

## Correlation of clinical signs and magnetic resonance imaging findings in patients with lumbar spondylosis

Lale Altan<sup>1</sup>, Burcu Metin Ökmen<sup>2</sup>, Tiraje Tuncer<sup>3</sup>, Dilşad Sindel<sup>4</sup>, Hasan Fatih Çay<sup>5</sup>, Simin Hepgüler<sup>6</sup>, Selda Sarıkaya<sup>7</sup>, Figen Ayhan<sup>8</sup>, Ajda Bal<sup>9</sup>, Meral Bilgilişoy<sup>10</sup>, Erhan Çapkın<sup>11</sup>, Lale Cerrahoğlu<sup>12</sup>, Remzi Çevik<sup>13</sup>, Deniz Dülgeroğlu<sup>9</sup>, Berrin Durmaz<sup>6</sup>, Tuncay Duruöz<sup>14</sup>, Gülcan Gürer<sup>15</sup>, Savaş Gürsoy<sup>16</sup>, Sami Hizmetli<sup>17</sup>, Cahit Kaçar<sup>3</sup>, Ece Kaptanoğlu<sup>18</sup>, Hilal Ecesoy<sup>19</sup>, Meltem Melikoğlu<sup>20</sup>, Kemal Nas<sup>21</sup>, Hakan Nur<sup>22</sup>, Şüheda Özçakır<sup>1</sup>, Nilay Şahin<sup>23</sup>, Özlem Şahin<sup>24</sup>, Merih Sarıdoğan<sup>25</sup>, Ömer Faruk Şendur<sup>26</sup>, İlhan Sezer<sup>3</sup>, Gülnur Taşçı Bozbaş<sup>27</sup>, Canan Tıkız<sup>12</sup>, Hatice Uğurlu<sup>28</sup>

<sup>1</sup>Department of Physical Medicine and Rehabilitation, Division of Rheumatology, Uludağ University School of Medicine, Bursa, Türkiye

<sup>2</sup>Department of Physical Medicine and Rehabilitation, University of Health Sciences, Bursa Yüksek İhtisas Training and Research Hospital, Bursa, Türkiye

<sup>3</sup>Department of Physical Medicine and Rehabilitation, Division of Rheumatology, Akdeniz University Faculty of Medicine, Antalya, Türkiye

<sup>4</sup>Department of Physical Medicine and Rehabilitation, Istanbul University, Istanbul Faculty of Medicine, Istanbul, Türkiye

<sup>5</sup>Department of Physical Medicine and Rehabilitation, Division of Rheumatology, University of Health Sciences, Antalya Training and Research Hospital, Antalya, Türkiye

<sup>6</sup>Department of Physical Medicine and Rehabilitation, Ege University Faculty of Medicine, Izmir, Türkiye

<sup>7</sup>Department of Physical Medicine and Rehabilitation, Bülent Ecevit University Faculty of Medicine, Zonguldak, Türkiye

<sup>8</sup>Department of Physical Medicine and Rehabilitation, Atılım University Medical School, Ankara, Türkiye

<sup>9</sup>Department of Physical Medicine and Rehabilitation, University of Health Sciences Dışkapı Yıldırım Beyazıt Training and Research Hospital, Ankara, Türkiye

<sup>10</sup>Department of Physical Medicine and Rehabilitation, Health Science University, Antalya Training and Research Hospital, Antalya, Türkiye

<sup>11</sup>Department of Physical Medicine and Rehabilitation, Karadeniz Technical University Faculty of Medicine, Trabzon, Türkiye

<sup>12</sup>Department of Physical Medicine and Rehabilitation, Celal Bayar University Faculty of Medicine, Manisa, Türkiye

<sup>13</sup>Department of Physical Medicine and Rehabilitation, Dicle University Faculty of Medicine, Diyarbakır, Türkiye

<sup>14</sup>Department of Physical Medicine and Rehabilitation, Division of Rheumatology, Marmara University Faculty of Medicine, Istanbul, Türkiye

<sup>15</sup>Department of Physical Medicine and Rehabilitation, Division of Rheumatology, Adnan Menderes University Faculty of Medicine, Aydın, Türkiye

<sup>16</sup>Department of Physical Medicine and Rehabilitation, Gaziantep University Faculty of Medicine, Gaziantep, Türkiye

<sup>17</sup>Department of Physical Medicine and Rehabilitation, Division of Rheumatology, Cumhuriyet University Faculty of Medicine, Sivas, Türkiye

<sup>18</sup>Department of Physical Medicine and Rehabilitation, Division of Rheumatology, Başkent University Faculty of Medicine, Zübeyde Hanım Hospital, Izmir, Türkiye

<sup>19</sup>Department of Physical Medicine and Rehabilitation, Division of Rheumatology, Karamanoğlu Mehmetbey University Faculty of Medicine, Konya, Türkiye

<sup>20</sup>Department of Physical Medicine and Rehabilitation, Division of Rheumatology, Atatürk University Faculty of Medicine, Erzurum, Türkiye

<sup>21</sup>Department of Physical Medicine and Rehabilitation, Division of Rheumatology and Immunology, Sakarya University Faculty of Medicine, Sakarya, Türkiye

<sup>22</sup>Department of Physical Medicine and Rehabilitation, Akdeniz University Faculty of Medicine, Antalya, Türkiye

<sup>23</sup>Department of Physical Medicine and Rehabilitation, Balıkesir University Faculty of Medicine, Balıkesir, Türkiye

<sup>24</sup>Department of Physical Medicine and Rehabilitation, Cumhuriyet University Faculty of Medicine, Sivas, Türkiye

<sup>25</sup>Department of Physical Medicine and Rehabilitation, Istanbul Üniversitesi-Cerrahpaşa, Cerrahpaşa Tıp Fakültesi, Istanbul, Türkiye

<sup>26</sup>Department of Physical Medicine and Rehabilitation and Algology, Medicana International Hospital, Izmir, Türkiye

<sup>27</sup>Department of Physical Medicine and Rehabilitation, Adnan Menderes University Faculty of Medicine, Aydın, Türkiye

<sup>28</sup>Department of Physical Medicine and Rehabilitation, Necmettin Erbakan University Meram Faculty of Medicine, Konya, Türkiye

**Correspondence:** Burcu Metin Ökmen, MD.

**E-mail:** burcumetinokmen@gmail.com

**Received:** November 18, 2022

**Accepted:** January 23, 2023

**Published online:** February 15, 2023

**Citation:** Altan L, Metin Ökmen B, Tuncer T, Sindel D, Çay HF, Hepgüler S, et al. Correlation of clinical signs and magnetic resonance imaging findings in patients with lumbar spondylosis. ArchRheumatol2023;38(4):512-520.doi:10.46497/ArchRheumatol.2023.9806.

This is an open access article under the terms of the Creative Commons Attribution-NonCommercial License, which permits use, distribution and reproduction in any medium, provided the original work is properly cited and is not used for commercial purposes (<http://creativecommons.org/licenses/by-nc/4.0/>).

**ABSTRACT**

**Objectives:** The purpose of the study was to contribute further to this debated topic by investigating the correlation of magnetic resonance imaging (MRI) findings with the clinical picture in lumbar spondylosis patients.

**Patients and methods:** This multicenter retrospective study (as part of the epidemiological project of the TLAR-OASG [Turkish League Against Rheumatism-Osteoarthritis Study Group]) included 514 patients (101 males, 413 females; mean age:  $63.6 \pm 10.8$  years; range, 40 to 85 years) who were diagnosed as lumbar spondylosis by clinical examination and direct X-ray between December 2016 and June 2018. Demographic characteristics of patients, Visual Analog Scale for pain, presence of radiating pain, Roland-Morris disability questionnaire, straight leg raise test, deep tendon reflexes, neurogenic intermittent claudication symptoms, any decrease of muscle strength, and abnormality of sensation were recorded. Lumbar MRI findings of the patients were recorded as positive or negative in terms of disc herniation, intervertebral disc degeneration, root compression, osteophytes, spinal stenosis. Statistical analysis was done to assess the correlation between the clinical symptoms, physical examination, and MRI findings.

**Results:** Correlation analysis of the MRI results and the clinical findings showed a significant correlation between straight leg raise test and root compression ( $p < 0.001$ ,  $r = 0.328$ ) and a significant correlation between neurogenic intermittent claudication and spinal stenosis ( $p < 0.001$ ,  $r = 0.376$ ). Roland-Morris disability questionnaire had a significant correlation with all MRI findings ( $p < 0.05$ ,  $r < 0.200$ ).

**Conclusion:** The results of this study corroborate the notion that diligent patient history and physical examination are more valuable than MRI findings, even though a higher incidence of abnormal MRI findings have been obtained in patients with disability and dermatomal radiating pain.

**Keywords:** Clinical manifestations, magnetic resonance imaging, Roland-Morris disability questionnaire, screening, spondylosis.

Low back pain (LBP) is one of the most common health problems and is known to affect two-thirds of the adult population at least once in their lifetime.<sup>1</sup> LBP becomes a chronic condition and causes disability in 10% of the patients, creating further burden on the affected individuals, their families, and the society by increasing the costs of medical expenses, insurance, loss of productivity, and disability compensation.<sup>2,3</sup>

Lumbar spondylosis (LS) is a chronic noninflammatory condition characterized by degenerative changes in the discs or facet joints. The incidence of intervertebral disc degeneration (IDD) is 10% in the patients at age 50 but increases up to 60% around 70 years of age.<sup>4</sup> These degenerative changes in the lumbar spine are a major etiological factor in the development of LBP and disability in the elderly population.<sup>5</sup>

Intervertebral disc degeneration is strongly related to LBP, and while it is asymptomatic in most cases, it may give rise to sciatalgia in some cases and to spinal stenosis in the long term, which is an important cause of pain and disability particularly in elderly patients.<sup>6,7</sup> The clinical picture in LS patients include discomfort in the lower back, radiating leg pain, and neurogenic intermittent claudication (NIC).<sup>8</sup>

Lumbar spondylosis diagnosis is made by clinical examination and imaging methods. Joint movement may be restricted and painful. Root compression symptoms may accompany the clinical picture. Detection of degenerative changes in the lumbar X-rays, such as osteophytes, intervertebral narrowing, and subchondral sclerosis, support

the diagnosis.<sup>9</sup> Magnetic resonance imaging (MRI) is the best imaging tool for the assessment of detailed structural changes in the spinal canal, the ligaments, the discs, and the nerve roots.<sup>10</sup> However, in studies examining MRI findings in asymptomatic individuals, it was reported that a significant proportion of patients had bulging, annular tears, facet arthropathies, and it was emphasized that degenerative changes increased with age.<sup>11</sup> Weiner et al.<sup>12</sup> have pointed to the excessive diagnostic tests in elderly patients with LBP and emphasized unnecessary employment of MRI in most of the patients, which contributed substantially to the increased health costs. It is crucial to delineate the correlation between the imaging findings, the history, and the physical examination of the patients when the high prevalence of disc protrusion and degenerative spinal stenosis (SS) in elderly patients is considered.<sup>7,13</sup> Although MRI is a proven method for precisely detecting the structural changes, correlation of MRI findings with patient history and clinical condition is still debated.<sup>14</sup>

There are several clinical studies in the literature focusing on the clinical findings in radiculopathy,<sup>15-17</sup> but there is limited evidence on the correlation of MRI findings with patient history and clinical symptoms in the patients with LS.<sup>18</sup> The purpose of our study was to contribute further to this debated topic by investigating the correlation of MRI findings with the clinical picture in LS patients. We also aimed to determine which findings are significant in LS patients, when MRI should be requested, and clinical findings for which an

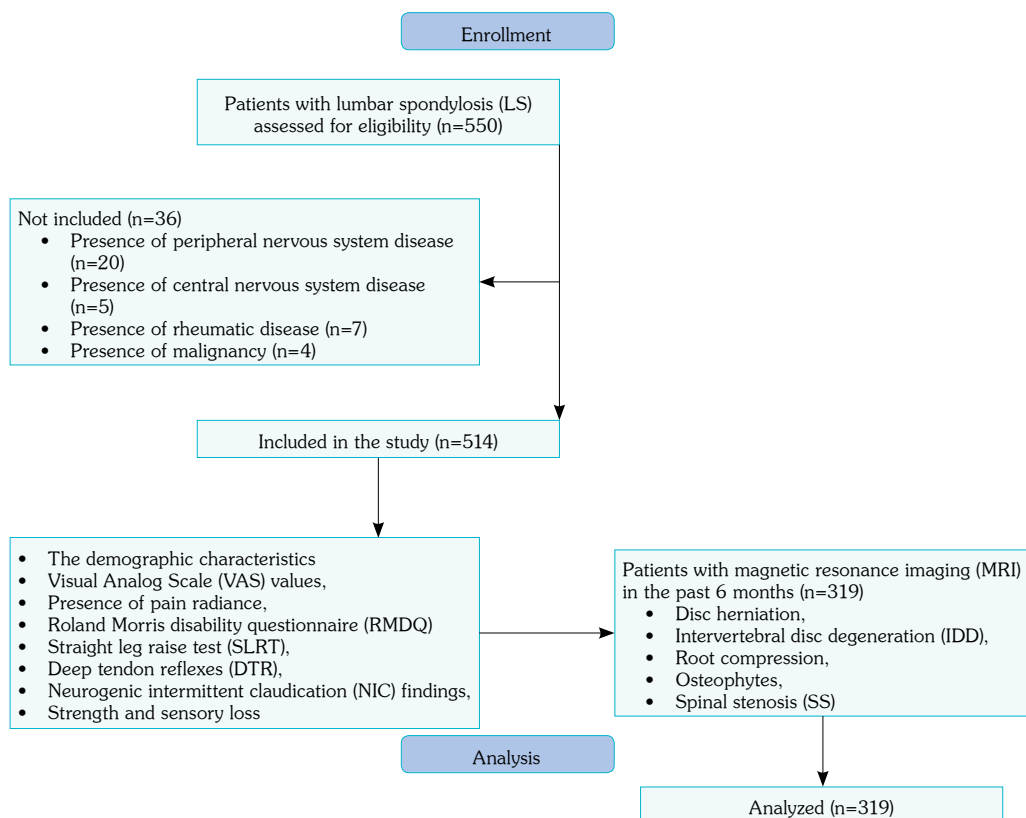
expensive diagnostic method such as MRI is unnecessary.

## PATIENTS AND METHODS

The retrospective study was conducted between December 2016 and June 2018. The patients who applied to the physical medicine and rehabilitation outpatient clinics of 33 university or training and research hospitals (as part of the epidemiological project of the TLAR-OASG [Turkish League Against Rheumatism-Osteoarthritis Study Group]) with complaints of chronic LBP and diagnosed as LS by clinical examination and direct X-ray were evaluated for eligibility. The radiological findings (osteophytes on X-ray, narrowing of intervertebral joints, and subchondral sclerosis) of patients aged between 40 to 85 years with chronic low back or leg pain who were suspected of having LS by a clinician were evaluated, and those with the diagnosis of LS were included. The patients with peripheral and central nervous system diseases,

inflammatory rheumatic disease, metabolic bone diseases (Paget's disease, osteomalacia, and hyperparathyroidism), chronic thyroid, renal, and liver disease, those using drugs that increase bone loss, such as glucocorticoids and anticonvulsants, atherosclerotic occlusive peripheral vascular disease, spinal tumor, restless legs syndrome, and malignancy were excluded from the study.

Of the 550 evaluated patients, 36 patients were not eligible for participation; thus, 514 patients (101 males, 413 females; mean age:  $63.6 \pm 10.8$  years; range, 40 to 85 years) were included in the study. Demographic characteristics of the patients were recorded. Visual Analog Scale (VAS) values for pain during the day (at rest and with movement) and at night, presence of radiating pain, Roland Morris disability questionnaire (RMDQ) for functional status evaluation, straight leg raise test (SLRT) for sciatalgia, deep tendon reflexes (DTRs; as hypoactive, normal, or hyperactive), NIC findings, and motor strength and sensory loss were recorded. MRI findings of patients who already had a recent (past six months) lumbar MRI



**Figure 1.** Study flowchart.

were analyzed. MRI findings were recorded from reports evaluated and written by radiologists. Lumbar MRI findings (disc herniation, IDD, root compression, osteophyte formation, and SS) of the patients were recorded as positive or negative. The patients with available MRI findings included in the final analysis, which evaluated the relationship between patient history, physical examination, and lumbar MRI findings, are demonstrated in the study's flowchart (Figure 1).

Roland Morris disability questionnaire is a questionnaire developed to evaluate functional disabilities in patients with LBP. In the questionnaire consisting of 24 sentences about functional deficiencies, patients are asked to answer each sentence as "yes" if it fits their situation, and "no" if it does not. Calculating "yes" answers as "1" and "no" answers as "0", the total score is between 0-24, with a higher score indicating more disability.<sup>19</sup> The validity and reliability study of this questionnaire was conducted in our country.<sup>20</sup>

### Statistical analysis

Data analysis was performed using the IBM SPSS version 22.0 (IBM Corp., Armonk, NY, USA) software. While evaluating the study data, demographic characteristics were measured with descriptive statistical tests. The conformity of the data to the normal distribution was evaluated with the Shapiro-Wilk test. Pearson's correlation analysis test was applied for correlation analysis as it was observed that the data were normally distributed. A *p* value <0.05 was considered statistically significant.

## RESULTS

The mean body mass index (BMI) was  $30.58 \pm 5.27$  kg/m<sup>2</sup>. Demographic data and the clinical findings of the patients are listed in Table 1. The mean VAS scores for pain during motion and resting pain were  $6.63 \pm 1.86$  and  $3.51 \pm 2.22$ , respectively (Table 1).

Straight leg raise was positive in 115 (22.50%) patients, 421 (82.07%) patients had normal DTRs, 345 (67.12%) patients showed positive NIC findings, 422 (82.1%) patients had no sensory loss, and 467 (91.03%) patients had no motor loss (Table 1).

An MRI performed during the past six months was available for 319 patients. According to the MRI reports, 245 (76.8%) had disc hernia, 285 (89.3%) had IDD, 149 (46.7%) had root compression, 256 (80.3%) had osteophytes, and 119 (37.3%) showed SS findings (Table 2).

Evaluation of the MRI results of the 90 patients who had a positive SLR showed disc hernia in

**Table 1.** Demographic characteristics and clinical findings of the patients (n=514)

	n	%	Mean±SD
Age (year)			63.6±10.8
Sex			
Female	413	80.4	
Body mass index (kg/m <sup>2</sup> )			30.6±5.3
Morning stiffness			
No	180	35.02	
<30 min	299	58.17	
>30 min	35	6.81	
Disc herniation in past			
No	285	55.4	
Yes	219	42.6	
Disc herniation operation in past			
No	463	90.1	
Yes	39	7.6	
VAS at motion			6.6±1.9
VAS at rest			3.5±2.2
VAS at night			3.2±2.6
Radiating of pain			
No	150	29.18	
Yes	364	70.82	
RDQ			14.7±6.2
SLRT			
Negative	396	77.50	
Positive	115	22.50	
DTR			
Normal	421	82.07	
Hypoactive	84	16.37	
Hyperactive	8	1.56	
NIC			
No	345	67.12	
Yes	169	32.88	
Loss of sensory			
No	422	82.10	
Yes	92	17.90	
Loss of strength			
No	467	91.03	
Yes	46	8.97	

SD: Standard deviation; VAS: Visual Analog Scale; RDQ: Roland-Morris Disability Questionnaire; SLRT: Straight Leg Raise Test; DTR: Deep Tendon Reflex; NIC: Neurogenic Intermittent Claudication

**Table 2.** Rates of MRI findings in patients undergoing MRI (n=319)

	n	%
Disc herniation in MRI		
No	74	23.20
Yes	245	76.80
IDD in MRI		
No	34	10.70
Yes	285	89.30
Root compression in MRI		
No	170	53.30
Yes	149	46.70
Osteophytes in MRI		
No	63	19.70
Yes	256	80.30
SS in MRI		
No	200	62.70
Yes	119	37.30

MRI: Magnetic resonance imaging; IDD: Intervertebral disc degeneration; SS: Spinal stenosis.

**Table 3.** Magnetic resonance imaging findings in straight leg raise test-positive patients

	n	%
Disc herniation in MRI		
No	9	10.00
Yes	81	90.00
IDD in MRI		
No	8	8.90
Yes	82	91.10
Root compression in MRI		
No	25	27.80
Yes	65	72.20
Osteophytes in MRI		
No	13	14.40
Yes	77	85.60
SS in MRI		
No	53	58.90
Yes	37	41.10

MRI: Magnetic resonance imaging; IDD: Intervertebral disc degeneration; SS: Spinal stenosis.

**Table 4.** Correlation of MRI findings and clinical findings

	Disc herniation in MRI	IDD in MRI	Root compression in MRI	Osteophytes in MRI	SS in MRI
SLRT					
r	0.200	0.041	0.328	0.091	0.060
p	<0.001*	0.468	<0.001*	0.108	0.284
VAS at motion					
r	0.193	0.111	0.228	0.002	0.137
p	0.001*	0.048*	<0.001*	0.975	0.014*
VAS at rest					
r	0.029	0.034	0.074	0.060	0.026
p	0.601	0.546	0.185	0.284	0.638
Loss of sensory					
r	0.087	0.031	0.218	0.027	0.137
p	0.123	0.582	<0.001*	0.625	0.015*
Loss of strength					
r	0.042	0.018	0.137	0.092	0.101
p	0.461	0.749	0.015*	0.102	0.073
Loss of DTR					
r	0.143	0.079	0.154	0.101	0.130
p	0.011*	0.160	0.006*	0.069	0.020*
Radiating of pain					
r	0.195	0.151	0.192	0.148	0.089
p	<0.001*	0.007*	0.001*	0.008*	0.114
NIC					
r	0.101	0.068	0.165	0.174	0.376
p	0.071	0.229	0.003*	0.002*	<0.001*
RMDQ					
r	0.118	0.120	0.193	0.153	0.187
p	0.037*	0.034*	0.001*	0.007*	0.001*

MRI: Magnetic resonance imaging; IDD: Intervertebral disc degeneration; SS: Spinal stenosis; SLRT: Straight Leg Raise Test; VAS: Visual Analog Scale; DTR: Deep tendon reflex; NIC: Neurogenic intermittent claudication; RMDQ: Roland-Morris disability questionnaire; \* p-value of less than 0.05 was considered statistically significant.



81 (90%) patients, IDD in 91.10%, and root compression in 72.20% (Table 3).

Correlation analysis of the MRI results and the clinical findings showed a weak but significant correlation between SLRT and disc hernia ( $p < 0.001$ ,  $r = 0.2$ ) and root compression ( $p < 0.001$ ,  $r = 0.328$ ), and between pain during motion and disc hernia ( $p < 0.001$ ,  $r = 0.2$ ), IDD ( $p = 0.048$ ,  $r = 0.111$ ), root compression ( $p < 0.001$ ,  $r = 0.228$ ), and SS ( $p = 0.014$ ,  $r = 0.137$ , Table 4).

There was no significant correlation between MRI results and resting pain ( $p > 0.05$ ). A weak but significant correlation was found between sensory loss and root compression ( $p < 0.001$ ,  $r = 0.218$ ) and SS ( $p = 0.015$ ,  $r = 0.137$ ), between motor loss and root compression ( $p = 0.015$ ,  $r = 0.137$ ), and between radiating pain and all MRI findings ( $p < 0.05$ ), except for SS. NIC showed a weak but significant correlation with root compression ( $p = 0.003$ ,  $r = 0.165$ ) and osteophytes ( $p = 0.002$ ,  $r = 0.174$ ), and a moderate and significant correlation with SS ( $p < 0.001$ ,  $r = 0.376$ , Table 4). RMDQ had a weak but significant correlation with all MRI findings ( $p < 0.05$ ,  $r < 0.200$ , Table 4).

## DISCUSSION

The results of our study showed that 70% of the patients with LBP due to LS had dermatomal radiation, one-third complained of NIC and had positive SLR test results, and most of them had normal neurological findings. There was also a strong statistically significant correlation between NIC and SS, as well as between SLRT and root compression.

The incidence of LS is known to increase with age, and 75% of the adult population have been reported to have LS findings.<sup>21</sup> IDD is asymptomatic in most cases,<sup>7</sup> but it may cause local pain and even dermatomal radiating pain with disc herniation and constriction of the foramina.<sup>22</sup> With advancing age, the intervertebral discs become dehydrated and flat and transfers the increased axial load to the facet joints, which leads to hypertrophy of these joints, osteophyte formation, and thickening of the ligamentum flavum. These changes cause the narrowing of the spinal canal, lateral

recesses, and neural foramina, thus lumbar stenosis.<sup>23,24</sup> NIC, or pseudoclaudication, which was observed in one-third of the patients in our study, is the most common symptom of LS and may substantially restrict the mobility by causing back and leg pain and muscle weakness.<sup>25</sup>

Magnetic resonance imaging has been found to be highly accurate and effective in the comparative assessment of spine morphology and the clinical picture of LBP.<sup>10</sup> The MRI results showed relatively high incidence of IDD (91%), disc hernia (90%), osteophytes (72%), and root compression (70%) in our patient population. In one of the few studies investigating the MRI findings in LS patients, Siddiqui et al.<sup>18</sup> reported disc hernia according to MRI findings in 89% and root or thecal sac compression in 73% of the patients, who had a significantly younger age average (mean age: 47 years) than our patients. They found severe root compression in 48 (40%) patients and observed that root compression and disc extrusion was correlated with pain radiating below the knee. We also observed such correlation between the dermatomal radiating pain and disc hernia, IDD, root compression, and existence of the osteophytes, corroborating the significance of this clinical symptom as a clue for severe pathological conditions.

The indication and timing of MRI in patients with back pain has been a debated topic. Evidence-based clinical guides have suggested the indication for MRI in the "red flags" (including infection, cancer, and cauda equina syndrome) but not in patients with nonspecific LBP.<sup>26</sup> These guides also maintain that MRI should be delayed in patients with a probable diagnosis of disc hernia or SS according to the consistent clinical symptoms and findings to allow the natural course of healing, which is observed in 50% of the disc hernia and radiculopathy cases.<sup>27</sup>

These guides emphasize that since pathological MRI findings can be detected in healthy people not infrequently, unnecessary imaging might lead to overdiagnosis and overtreatment, which then may create a burden both on the patient and the health insurance system.<sup>28</sup> Cheung et al.<sup>29</sup> detected lumbar IDD in 40% of the people under the age of 30 and 90% of the people in the age range of 50 to

55 in a study where they performed MRI on 1,453 healthy subjects. In another study with a smaller population, 38% of the healthy subjects were found to have a pathological condition in at least one disc according to MRI.<sup>13</sup> Therefore, in patients who do not have red flags and are not considered for operation, it can be concluded that there is more harm than benefit of MRI.

Deyo et al.<sup>30</sup> reported in 2009 that employment of MRI had increased by 307% in the past 12 years, a significant contradiction to the suggestion of the above guides. Weiner et al.<sup>12</sup> stated that MRI was performed in 61% of the LBP patients with no diagnostic red flags and that caused a 33.2% increase in health expenses. Webster et al.<sup>28</sup> suggested that physicians and patients should be informed and educated about the risks of unnecessary medical procedures that may be imposed by nonspecific employment of MRI during the early clinical stages.

The complaint of pain during motion showed a low but statistically significant correlation with the MRI findings of disc hernia, IDD, root compression, and SS, but no correlation was found for the presence of osteophytes and any MRI finding in our study. Radiating pain was correlated with disc pathology and osteophytes, but resting pain had no correlation with any MRI finding. These results suggest that MRI may have a diagnostic value in radiating pain and pain during motion.

Endean et al.<sup>11</sup> concluded in a meta-analysis focusing on the correlation of back pain with the abnormal MRI findings that disc protrusion, nerve root compression, and annular tears might indeed be correlated with back pain; however, there was no strong indication at an individual level for attributing these abnormal findings with certainty to the underlying pathology. They found the odd ratio in the studies investigating the correlation of IDD with LBP to range between 1.39 and 8.7 and calculated their meta-estimate of the odds ratio as 2.5. They reported the incidence of SS as 3 to 13% in patients without back pain in contrast to 31% in patients with back pain, which is close to the results obtained in our study.<sup>11</sup>

Indications for conservative treatment versus surgery in LBP patients depend on the existence and severity of nerve root compression.<sup>1</sup> The incidence of symptomatic lumbar disc herniation (LDH) is known to be 1 to 3% in the general

population, yet only 15 to 20% of these cases have an indication for surgery.<sup>31</sup> The incidence of LDH and root compression according to MRI results was 76.80% and 46.70% in our study; however, strength was normal in 91%, DTR was normal in 82%, and 78% had no sensory deficit. Loss of strength was only correlated with root compression. This finding points to the lack of a strong correlation between MRI findings and clinical symptoms, particularly in elderly patients, and the priority of the clinical picture in treatment decisions. We observed a significant correlation between the loss of DTR and SS, as well as with disc hernia and root compression. This emphasizes the importance of including SS in diagnosis in the presence of loss of DTR in elderly patients. For this reason, the patient's history should be taken very carefully, specifically in elderly patients, degenerative findings should be questioned, and clinical examination should be performed diligently.

Lower extremity neurodynamic tests (femoral nerve stretch test and SLRT) are known to be effective in the lumbosacral radiculopathy diagnosis.<sup>32</sup> Based on this, we used SLRT in our study. In the correlation of MRI findings and SLRT, a statistically positive correlation was found only between disc herniation and root compression. However, when we examined the MRI values of 90 patients with SLRT positivity, we found the rate of patients with root compression to be 72.2%, while surprisingly, we detected much higher rates of IDD (91.10%), LDH (90%), and osteophytes (85.60%). This may be interpreted as an indication of the low reliability of SLRT in detection of radiculopathy findings, particularly in the elderly population. It is also possible that the existence of osteoarthritis (coxarthrosis or gonarthrosis) accompanying LS may have interfered with the evaluation of SLRT.

We found a significant correlation between all MRI parameters and the RMDQ, which reflects the disability status of the patients with back pain. Arana et al.<sup>33</sup> employed a different disability score in their study and did not find any correlation with disability and MRI findings, except for spondylolisthesis. Carragee<sup>34</sup> employed MRI and discography in a prospective study in patients with resistant LBP and could not find a correlation between MRI findings and negative clinical conditions according to the Oswestry disability

index. The contradictory results obtained in our study may be due to the employment of a different disability index; nevertheless, our results suggest a significant correlation between higher disability scores and abnormal MRI findings.

The major limitations of this study are the interpretation of MRI results by different radiologists owing to its multicentric status and the lack of interrater analysis. In addition, the lack of MRIs for all patients, the inability to evaluate all MRIs by a single radiologist or physiatrist since it is a multicenter study, and the inability to evaluate the use of standard diagnostic criteria for radiology can be counted among the limitations.

In conclusion the results of this study corroborate the notion that diligent patient history and physical examination are more valuable than MRI findings, even though a higher incidence of abnormal MRI findings have been obtained in patients with disability and dermatomal radiating pain. The indications for MRI should be in accordance with the guidelines, and the causative relationship between the MRI findings and the clinical picture should be unequivocally defined, especially before surgical intervention.<sup>35</sup>

**Ethics Committee Approval:** The study protocol was approved by the Akdeniz University Faculty of Medicine Ethics Committee (date: 20.01.2016, no: 56). The study was conducted in accordance with the principles of the Declaration of Helsinki.

**Patient Consent for Publication:** Informed consent was obtained from all individual participants included in the study.

**Data Sharing Statement:** The data that support the findings of this study are available from the corresponding author upon reasonable request.

**Author Contributions:** All authors contributed to the study design, material preparation, data collection, analysis, interpretation and writing of the manuscript and take full responsibility for the integrity of the study and the final manuscript. All authors read and approved the final manuscript.

**Conflict of Interest:** The authors declared no conflicts of interest with respect to the authorship and/or publication of this article.

**Funding:** The authors received no financial support for the research and/or authorship of this article.

## REFERENCES

1. Jarvik JG, Deyo RA. Diagnostic evaluation of low back pain with emphasis on imaging. *Ann Intern Med* 2002;137:586-97. doi: 10.7326/0003-4819-137-7-200210010-00010.
2. Maniadakis N, Gray A. The economic burden of back pain in the UK. *Pain* 2000;84:95-103. doi: 10.1016/S0304-3959(99)00187-6.
3. van Tulder MW, Koes BW, Bouter LM. A cost-of-illness study of back pain in The Netherlands. *Pain* 1995;62:233-40. doi: 10.1016/0304-3959(94)00272-G.
4. Miller JA, Schmatz C, Schultz AB. Lumbar disc degeneration: Correlation with age, sex, and spine level in 600 autopsy specimens. *Spine (Phila Pa 1976)* 1988;13:173-8.
5. Kelsey JL, White AA 3rd. Epidemiology and impact of low-back pain. *Spine (Phila Pa 1976)* 1980;5:133-42. doi: 10.1097/00007632-198003000-00007.
6. Luoma K, Riihimäki H, Luukkonen R, Raininko R, Viikari-Juntura E, Lamminen A. Low back pain in relation to lumbar disc degeneration. *Spine (Phila Pa 1976)* 2000;25:487-92. doi: 10.1097/00007632-200002150-00016.
7. Boden SD, Davis DO, Dina TS, Patronas NJ, Wiesel SW. Abnormal magnetic-resonance scans of the lumbar spine in asymptomatic subjects. A prospective investigation. *J Bone Joint Surg [Am]* 1990;72:403-8.
8. Urban JP, Roberts S. Degeneration of the intervertebral disc. *Arthritis Res Ther* 2003;5:120-30. doi: 10.1186/ar629.
9. Varlotta GP, Lefkowitz TR, Schweitzer M, Errico TJ, Spivak J, Bendo JA, et al. The lumbar facet joint: A review of current knowledge: Part 1: Anatomy, biomechanics, and grading. *Skeletal Radiol* 2011;40:13-23. doi: 10.1007/s00256-010-0983-4.
10. Chawalparit O, Churojana A, Chiewvit P, Thanapipatsir S, Vamvanij V, Charnchaowanish P. The limited protocol MRI in diagnosis of lumbar disc herniation. *J Med Assoc Thai* 2006;89:182-9.
11. Endean A, Palmer KT, Coggon D. Potential of magnetic resonance imaging findings to refine case definition for mechanical low back pain in epidemiological studies: A systematic review. *Spine (Phila Pa 1976)* 2011;36:160-9. doi: 10.1097/BRS.0b013e3181cd9adb.
12. Weiner DK, Kim YS, Bonino P, Wang T. Low back pain in older adults: Are we utilizing healthcare resources wisely? *Pain Med* 2006;7:143-50. doi: 10.1111/j.1526-4637.2006.00112.x.
13. Jensen MC, Brant-Zawadzki MN, Obuchowski N, Modic MT, Malkasian D, Ross JS. Magnetic resonance imaging of the lumbar spine in people without back pain. *N Engl J Med* 1994;331:69-73. doi: 10.1056/NEJM199407143310201.



14. Weiner BK, Patel R. The accuracy of MRI in the detection of lumbar disc containment. *J Orthop Surg Res* 2008;3:46. doi: 10.1186/1749-799X-3-46.
15. Iversen T, Solberg TK, Romner B, Wilsgaard T, Nygaard Ø, Waterloo K, et al. Accuracy of physical examination for chronic lumbar radiculopathy. *BMC Musculoskelet Disord* 2013;14:206. doi: 10.1186/1471-2474-14-206.
16. Suri P, Rainville J, Katz JN, Jouve C, Hartigan C, Limke J, et al. The accuracy of the physical examination for the diagnosis of midlumbar and low lumbar nerve root impingement. *Spine (Phila Pa 1976)* 2011;36:63-73. doi: 10.1097/BRS.0b013e3181c953cc.
17. Coster S, de Bruijn SF, Tavy DL. Diagnostic value of history, physical examination and needle electromyography in diagnosing lumbosacral radiculopathy. *J Neurol* 2010;257:332-7. doi: 10.1007/s00415-009-5316-y.
18. Siddiqui AH, Rafique MZ, Ahmad MN, Usman MU. Role of magnetic resonance imaging in lumbar spondylosis. *J Coll Physicians Surg Pak* 2005;15:396-9.
19. Roland M, Morris R. A study of the natural history of back pain. Part I: Development of a reliable and sensitive measure of disability in low-back pain. *Spine (Phila Pa 1976)* 1983;8:141-4. doi: 10.1097/00007632-198303000-00004.
20. Küçükdeveci AA, Tennant A, Elhan AH, Niyazoglu H. Validation of the Turkish version of the Roland-Morris Disability Questionnaire for use in low back pain. *Spine (Phila Pa 1976)* 2001;26:2738-43. doi: 10.1097/00007632-200112150-00024.
21. Battié MC, Videman T. Lumbar disc degeneration: Epidemiology and genetics. *J Bone Joint Surg Am* 2006;88 Suppl 2:3-9. doi: 10.2106/JBJS.E.01313.
22. Boos N, Weissbach S, Rohrbach H, Weiler C, Spratt KF, Nerlich AG. Classification of age-related changes in lumbar intervertebral discs: 2002 Volvo Award in basic science. *Spine (Phila Pa 1976)* 2002;27:2631-44. doi: 10.1097/00007632-200212010-00002.
23. Frymoyer JW, Moskowitz RW. Spinal degeneration. Pathogenesis and medical management. In: Frymoyer JW, editor. *The adult spine: principles and practice*. New York: Raven; 1991. p. 611-34.
24. Kirkaldy-Willis WH, Yong-Hing K. Lateral recess, lateral canal, and foraminal stenosis. In: Watkins RG, Collis JS, editors. *Lumbar discectomy and laminectomy*. Rockville (MD): Aspen Publishers Inc; 1987. p. 245-52.
25. Deer T, Sayed D, Michels J, Josephson Y, Li S, Calodney AK. A review of lumbar spinal stenosis with intermittent neurogenic claudication: Disease and diagnosis. *Pain Med* 2019;20(Suppl 2):S32-S44. doi: 10.1093/pm/pnz161.
26. Chou R, Qaseem A, Snow V, Casey D, Cross JT Jr, Shekelle P, et al. Diagnosis and treatment of low back pain: A joint clinical practice guideline from the American College of Physicians and the American Pain Society. *Ann Intern Med* 2007;147:478-91. doi: 10.7326/0003-4819-147-7-200710020-00006.
27. Vroomen PC, de Krom MC, Knottnerus JA. Predicting the outcome of sciatica at short-term follow-up. *Br J Gen Pract* 2002;52:119-23.
28. Webster BS, Bauer AZ, Choi Y, Cifuentes M, Pransky GS. Iatrogenic consequences of early magnetic resonance imaging in acute, work-related, disabling low back pain. *Spine (Phila Pa 1976)* 2013;38:1939-46. doi: 10.1097/BRS.0b013e3182a42eb6.
29. Cheung KM, Karppinen J, Chan D, Ho DW, Song YQ, Sham P, et al. Prevalence and pattern of lumbar magnetic resonance imaging changes in a population study of one thousand forty-three individuals. *Spine (Phila Pa 1976)* 2009;34:934-40. doi: 10.1097/BRS.0b013e3181a01b3f.
30. Deyo RA, Mirza SK, Turner JA, Martin BI. Overtreating chronic back pain: Time to back off? *J Am Board Fam Med* 2009;22:62-8. doi: 10.3122/jabfm.2009.01.080102.
31. Jordan J, Konstantinou K, O'Dowd J. Herniated lumbar disc. *BMJ Clin Evid* 2009;2009:1118.
32. Tawa N, Rhoda A, Diener I. Accuracy of clinical neurological examination in diagnosing lumbo-sacral radiculopathy: A systematic literature review. *BMC Musculoskelet Disord* 2017;18:93. doi: 10.1186/s12891-016-1383-2.
33. Arana E, Martí-Bonmatí L, Vega M, Bautista D, Mollá E, Costa S, et al. Relationship between low back pain, disability, MR imaging findings and health care provider. *Skeletal Radiol* 2006;35:641-7. doi: 10.1007/s00256-006-0100-x.
34. Carragee EJ. Psychological and functional profiles in select subjects with low back pain. *Spine J* 2001;11:198-204. doi: 10.1016/s1529-9430(01)00050-x.
35. Omid-Kashani F, Hejrati H, Ariamanesh S. Ten important tips in treating a patient with lumbar disc herniation. *Asian Spine J* 2016;10:955-63. doi: 10.4184/asj.2016.10.5.955.