

Brucella Arthritis of Hip: A Case Report

Kalça Eklemine Brusella Artriti: Bir Olgu Sunumu

Özlem Altındağ, Fatma Sırmatel¹, Öcal Sırmatel²

Harran Üniversitesi Tıp Fakültesi Fiziksel Tıp ve Rehabilitasyon,
¹Enfeksiyon Hastalıkları ve ²Radyoloji Anabilim Dalı, Şanlıurfa, Türkiye

Abstract

Brucellosis is a zoonosis that may affect almost any organ, notably the musculo-skeletal, cardiovascular and central nervous systems, sometimes with serious complications. Osteoarticular involvement is the most common complication of brucellosis. However, it can be difficult to diagnose it due to its nonspecific manifestations in musculoskeletal system. The painful limitation of movement may be the only articular sign in the involvement of the joint in Brucellosis. In this study we described a child with hip involvement of brucellosis who did not have any other systemic symptoms of brucellosis. It is suggested that brucellosis should be considered for those patients who have live in endemic regions. (*Rheumatism 2007; 22: 40-2*)

Key words: Arthritis, brucellosis, hip involvement

Özet

Brusellozis, brusella gurubu bakterilerin oluşturduğu, enfeksiyöz bir hastalık olup bir çok organı özellikle de kas iskelet sistemi, kardiyovasküler sistem ve merkezi sinir sistemini etkileyerek ciddi komplikasyonlara neden olabilen bir hastalıktır. Osteoartriküler tutulum en sık komplikasyon olmakla birlikte spesifik olmayan bulgularla seyrettiğinden tanı konulması zordur. Brusella enfeksiyonunun, eklem bulgusu çoğu zaman sadece eklem hareket açıklığında kısıtlanma olabilir. Bu yazıda brusella enfeksiyonuna bağlı kalça artriti gelişen ve eklem yakınmaları dışında sistemik enfeksiyon bulgusu göstermeyen bir çocuk hasta tanımladık. Eklem yakınmaları ile karşımıza çıkan ve özellikle endemik bölgelerde yaşayan hastalar, brusellozis yönünden değerlendirilmelidir. (*Romatizma 2007; 22: 40-2*)

Anahtar kelimeler: Artrit, brusellozis, kalça eklemi tutulumu

Introduction

Brucellosis is a systemic infectious disease which is transmitted to humans through consumption of unpasteurised dairy product of infected animals (1). It is still a serious public health and socio-economic problem in many Mediterranean countries including Turkey. Musculoskeletal complications are important, owing to their high prevalence and also the associated functional sequelae (2). Osteoarticular involvement is common in Brucellosis, having been reported in 10% - 85% of cases (3). However, the clinical picture of joint involvement can be misleading, and rather non-specific. Sacroileitis, spondylitis, and large peripheric joints involvement may occur in brucellosis. Also it can be associated with osteomyelitis and paraspinal abscesses (4). The peripheral arthritis in Brucellosis is particularly common in children and young adults (2,5). The usual presentation involves a large peripheral joint monoarthritis. Patients usually have acute features of Bru-

cellosis, including fever, hepatosplenomegaly, lymphadenopathy, and painful limited joint motion in brucellar arthritis (6).

We report here a child with brucellar hip arthritis who has only joint complaints without any other systemic symptoms. Hip arthritis can occur in Brucellosis but there were a few studies and case reports about this subject (7). Brucellosis should be considered in children and young adults who have joint complaints even they don't have any other systemic symptom. Early diagnosis, prolonged treatment, and long term follow up is very important in Brucellosis.

Case Report

A 10-year-old boy from a village in southeastern Turkey was admitted with painful limited motion of right lower limb for two weeks. There was no history of trauma, and no family history of inflammatory joint disease.

On admission, his body temperature was 37 °C, and blood pressure and pulse rate were in normal limits. At physical examination, his right hip was held in flexion, with extension, internal rotation, and abduction causing severe pain. He had not any other systemic symptoms except fatigue. There was no swelling or pain of his other joints and axial skeleton, and sacroiliac joints were normal.

Laboratory results showed that erythrocyte sedimentation rate (ESR): 72mm/h, CRP: 18mg/l, leukocyte count: 8.500/mm³, antistreptolysin (ASO) and rheumatoid factor were within normal limits, antinuclear antibody was negative, blood urea levels, creatinin levels and liver function tests were normal, brucella standard tube agglutination test was negative, and no micro-organism grew in blood culture.

Plain radiographs of the right hip showed minimal soft tissue swelling, and magnetic resonance imaging of the right hip showed para-articular hyperintensities on the T2 weighted sequence (Fig. 1). Since the patient had not active synovial effusion in the hip joint, joint aspiration was not performed.

Detailed medical history revealed that the patient was living in an area endemic for brucellosis and frequently eats cheese made from raw milk. Standard tube agglutination test was done second time, the result was negative. Anti-Brucella Coombs test was performed two times with an interval of three days. The results were positive with a titer of 1/320 and 1/640.

The diagnosis of brucellosis was based on the joint complaints, magnetic resonance imaging of hip and significantly positive titres of coombs test for brucella.

The patient was hospitalized for 10 days and treated with rifampicin 300mg x 2/day, gentamycine 80mg/day, trimethoprim/sulfamehoxazole 160/800mg/day for 2 months. We determined the response to the treatment as the time to achieve a full range of pain free movement of the hip. Follow-up was continued to monitor clinical cure and relapse.

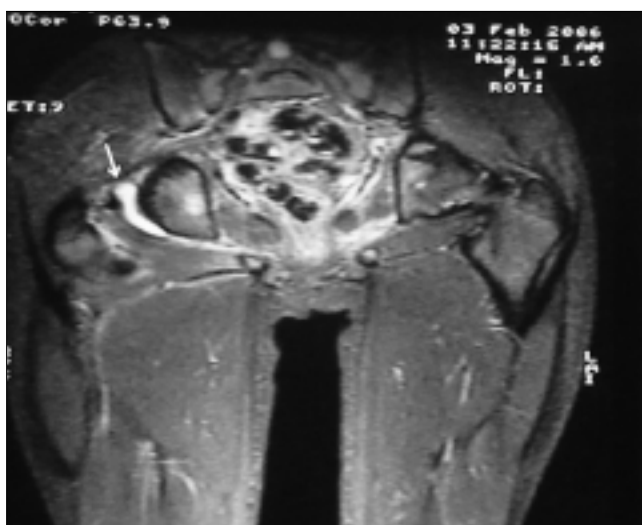


Figure 1. Magnetic resonance imaging of the right hip

Discussion

Brucellosis is a disorder of worldwide distribution, but occurs relatively frequently in Mediterranean countries (8). This case was originated from Southeastern Turkey, where the disease is endemic for Brucellosis. *Brucella melitensis* is the most infectious and pathogenetic agent and is responsible for almost all of the human disease in Turkey (9).

Brucella infection is associated with arthritis in 10-25% of patients. The most commonly affected joints are the sacroiliac joint (26%) and knee (25%) followed by hip (18%) and spine (8%) (10). Disease frequently presents with non-specific clinical manifestations such as fever, profuse sweating, polyarthromyalgia, and weight loss (11). In clinical practice, systemic complaints indicate brucellosis and diagnosis can be made based on blood testing for brucellosis. If brucella arthritis is the localized form of the disease, systemic symptoms may be absent (10).

Brucellosis is a systemic infection with a wide clinical spectrum, ranging from asymptomatic forms to severe cases causing death (12). Arthritis may usually present in association with acute or undulant systemic disease. A single painful joint, as seen in our patient with hip arthritis, without constitutional symptoms is an unusual condition in brucellosis. Because of indolent presentation and moderate local signs of inflammation, the diagnosis of localized brucellar arthritis is difficult.

Laboratory findings are variable, with a normal white cell count seen in 80% the erythrocyte sedimentation rate is increased in 30% of patients (3). The characteristic joint fluid feature is helpful in diagnosis of brucellar arthritis, but the isolation of brucella from synovial fluid is difficult due to the relative paucity of organisms present in specimens (13).

The standard agglutination test is the most widely used serological procedure, with a titre of > 1/160. We have done standard agglutination test for brucella two times but the results were false negative. There were a variety of serological tests, but at least two serological tests have to be combined to avoid false negative results. Usually, the serum agglutination test is used for the first screening and Coombs' test confirms its results (14).

In the present case, articular manifestations were the only symptoms of brucellosis, and systemic symptoms did not develop during the follow-up period. Clinicians should not overlook the possibility of brucella infection in children with arthritis. The diagnostic delay of brucellar arthritis can cause several complications in hip such as dislocation, avascular necrosis (3,15,16).

In conclusion, brucellosis should be considered in the differential diagnosis of arthritis in children, especially who comes from an area endemic for the disease. A detailed history of animal contact or the ingestion of unpasteurised milk or other products is required and appropriate serological tests should be done.

References

1. Corbel MJ. Recent advances in brucellosis. *J Med Microbiol* 1997;46:101-3.
2. Geyik MF, Gur A, Nas K, Cevik R, Sarac J, Dikici B, et al. Musculoskeletal involvement of brucellosis in different age groups: a study of 195 cases. *Swiss Med Wkly* 2002;132:98-105.
3. Mousa AR, Muhtaseb SA, Almudallal DS, Khodeir SM, Marafie AA, Marafie AA. Osteoarticular complications of brucellosis: a study of 169 cases. *Rev Infect Dis* 1987;9:531-43.
4. Ariza J, Gudiol F, Valverde J, Pallares R, Fernandez-Viladrich P, Rufi G, et al. Brucellar spondylitis: a detailed analysis based on current findings. *Rev Infect Dis* 1985;7:656-664.
5. Wise RI. Brucellosis in the United States. Past, present, and future. *JAMA* 1980;244:2318-22.
6. Tasova Y, Saltoglu N, Sahin G, Aksu HS. Osteoarticular involvement of brucellosis in Turkey. *Clin Rheumatol* 1999;18:214-9.
7. Bosilkovski M, Krteva L, Caparoska S, Dimzova M. Hip arthritis in brucellosis: a study of 33 cases in the Republic of Macedonia (FYROM). *Int J Clin Pract* 2004;58:1023-7.
8. Reitman CA, Watters WC. Spinal brucellosis: case report in the United States. *Spine* 2002;27:250-2.
9. Turgut M, Cullu E, Sendur OF, Guyrer G. Brucellar spine infection-four case reports. *Neurol Med Chir* 2004;44:562-7.
10. Khateeb MI, Araj GF, Majeed SA, Lulu AR. Brucella arthritis: a study of 96 cases in Kuwait. *Ann Rheum Dis* 1990;49:994-8.
11. Ozgocmen S, Ardicoglu A, Kocakoc E, Kiris A, Ardicoglu O. Paravertebral abscess formation due to brucellosis in a patient with ankylosing spondylitis. *Joint Bone Spine* 2001;68: 521-4.
12. Colmenero JD, Reguera JM, Martos F, Sanchez-De Mora D, Delgado M, Causse M, et al. Complications associated with Brucella melitensis infection: a study of 530 cases. *Medicine (Baltimore)* 1996;75:195-211.
13. McDermott M, O'Connell B, Mulvihill TE, Sweeney EC. Chronic Brucella infection of the supra-patellar bursa with sinus formation. *J Clin Pathol* 1994;47:764-6.
14. Al Dahouk S, Tomaso H, Nockler K, Neubauer H. Laboratory-based diagnosis of brucellosis-a review of the literature. Part II: serological tests for brucellosis. *Clin Lab* 2003;49:577-89.
15. Benjamin B, Khan MR. Hip involvement in childhood brucellosis. *J Bone Joint Surg* 1994;76:544-7.
16. Gedalia A, Howard C, Einhorn M. Brucellosis induced avascular necrosis of the femoral head in a 7 year old child. *Ann Rheum Dis* 1992;51:404-6.