

## Reflex Sympathetic Dystrophy Syndrome of the Ankle in Pregnancy

### *Gebelikte Ayak Bileğinin Refleks Sempatik Distrofi Sendromu*

Mehmet Karakoç, Özlem Altındağ<sup>1</sup>, Neslihan Soran<sup>1</sup>

Özel Yaşam Hastanesi, Fiziksel Tıp ve Reehabilitasyon Kliniği, Aksaray

<sup>1</sup>Harran Üniversitesi Tıp Fakültesi Fiziksel Tıp ve Rehabilitasyon Anabilim Dalı, Şanlıurfa, Türkiye

#### Abstract

Reflex sympathetic dystrophy (RSDS) is a type of arthropathy combining a painful syndrome with regional trophic disturbances. The condition primarily affects women during pregnancy, but it also affects middle-aged men. Although hip involvement is the most common form of the disease in pregnancy, other joints such as knee and ankle may be involved. Diagnosis is based on typical clinical and radiological observations. Pain may persist for six months or longer. Fracture is the major risk for the disease. Treatment consists of analgesics, protection against stress fractures, and the prevention of contractures. Reflex sympathetic dystrophy does not appear to affect the course of pregnancy but conclusion of the pregnancy is necessary for cure. We described a patient with pain and local osteopenia of the ankle occurring in the third trimester of pregnancy. We prefer the name reflex sympathetic dystrophy for this condition and we discussed the different terms which determine the same condition. (*Rheumatism 2007; 22: 76-9*)

**Key words:** Reflex sympathetic dystrophy, transient osteoporosis, pregnancy

#### Özet

Refleks Sempatik Distrofi (RSDS) bölgesel trofik bozukluklar ve ağrı ile seyreden bir artropatidir. Hastalık öncelikle gebelik döneminde kadınlarda fakat aynı zamanda orta yaşlı erkeklerde de ortaya çıkabilir. Hamilelik sırasında ortaya çıktığında kalça eklemi en sık tutulan eklem olmakla birlikte diz, ayak bileği gibi diğer eklemler de tutulabilir. Tanı genellikle klinik ve radyolojik bulgulara dayanılarak konur. Ağrı 6 ay ya da daha uzun sürebilir. En ciddi komplikasyonu tutulan bölgede kırık oluşmasıdır. Tedavi ağrının kesilmesi, stres kırıkları ve kontraktürlerin önlenmesinden oluşur. Gebelikte ortaya çıkan RSDS, gebeliğin seyrini değiştirmez ancak tedavisi için gebeliğin sonlanması genellikle gereklidir. Bu yazıda gebeliğin üçüncü trimestrinde ayak bileği ağrısı ve lokal osteopenisi olan bir hasta sunuldu. Biz hastalığı refleks sempatetik distrofi olarak isimlendirmeyi tercih ettik ve literatürde aynı hastalık için kullanılan farklı isimleri tartıştık. (*Romatizma 2007; 22: 76-9*)

**Anahtar kelimeler:** Refleks Sempatik Distrofi, geçici osteoporoz, hamilelik

#### Introduction

Reflex sympathetic dystrophy (RSD) is a pain syndrome that is characterized by autonomic, motor and sensory disturbances with unknown etiology that can encompass a wide range of manifestations in affected limbs (1). The disease usually characterized a self-limiting syndrome, but recurrence may be seen in other joints. Treatment consists of analgesics, protection against stress fractures, and physical therapy for prevention of complications. Transient osteoporosis is an uncommon condition which affects previously healthy women in the third trimester of pregnancy (2). There are several published similar cases which were named different terms such as transient osteoporosis, Sudeck's

atrophy, algodystrophy which determine this condition (3). Lequesne (1968) proposed a non-traumatic form of RSD. However, whether all terms were determine the same condition or not, remains to be explored.

This poorly understood disorder, which is frequently deceptive and sometimes clinically misleading especially in pregnant women, characterized by pain in the involved joint (5, 6). We described a woman who developed local osteoporosis in the ankle and foot during pregnancy.

#### Case Report

A 25 year old woman (gravida 3) at 30 weeks gestation was referred with pain on right foot and ankle. Her

pregnancy was otherwise uneventful. She had no history of trauma or preceding illness.

Physical examination was showed blue discoloration of the right leg distal to the knees. The skin felt cool and moist. There was marked tenderness below the knees to both light and deep palpation and to percussion. The pain was aggravated by weight-bearing and relieved with rest. Pulses were normal and there were no neurological deficits. Clinical examination revealed decreased skin temperature in the affected areas, change in skin color, and normal articular mobility. Marked hypersensitivity to touch and periarticular soft tissue swelling was evident around the ankles. Her gait was antalgic. No similar symptoms were occurred at prior pregnancies. She was no smoking and had no alcohol consumption. There was no family history for osteoporosis or bone disorders. She had not taken any drugs during pregnancy.

Laboratory evaluations were as follows: Hemoglobin: 11.2 g/dL (12-18 g/dl), ESR: 54 mm/1 h (0-15 mm/h), CRP: 15.3

mg/dL (0.0-0.8), white blood cell: 10 000/mm<sup>3</sup> Ca: 8.5 L (8.6-10.2 mg/dl), P: 3.2 (2.7-4.5 mg/dl), ALP: 115 (50-270 U/l), PTH: 41.30 (15-65pg/ml).

The patient refused any form of imaging during pregnancy. A healthy child was delivered at 40 weeks. After delivery, plain radiographs showed that diffuse osteopenia of her right foot and ankle (Figure 1). A magnetic resonance imaging (MRI) was performed. There was low signal intensity on T1-weighted images and high signal intensity on T2-weighted images in ankle and foot (Figure 2). In addition, MRI demonstrated changes consistent with bone marrow oedema affecting bone including the talus, cuboid, calcaneus and lateral cuneiform, and generalized surrounding soft tissue oedema. Repeat radiographs showed results similar to the first one. Bone mineral density revealed decreased bone mass, and dual energy X-ray absorpsiometry (DXA) measurement of bone density demonstrated osteopenia of the spine with a T score (femur): -2.2, BMD (femur): 0.607 g/cm<sup>2</sup>, T score (spine): -2.1, BMD (spine): 0.815 g/cm<sup>2</sup>. Plain radiographs of spine and MRI of hip were normal (Fig 3-4). Bone scintigram usually provides early diagnosis in transient regional osteoporosis. Scintigraphy was not performed in this patient, because we did not have a nuclear medical imaging system in our hospital.

The patient was advised to avoid weight bearing, and treated with a combination of salmon calcitonin at a dose of 200 U/l 3 times a week, and 1000 mg Calcium-800 mg vitamin D, and analgesics for four weeks. Symptoms were resolved over the next three weeks. MRI showed resolution of bone marrow oedema in foot and ankle bones (Figure 5).

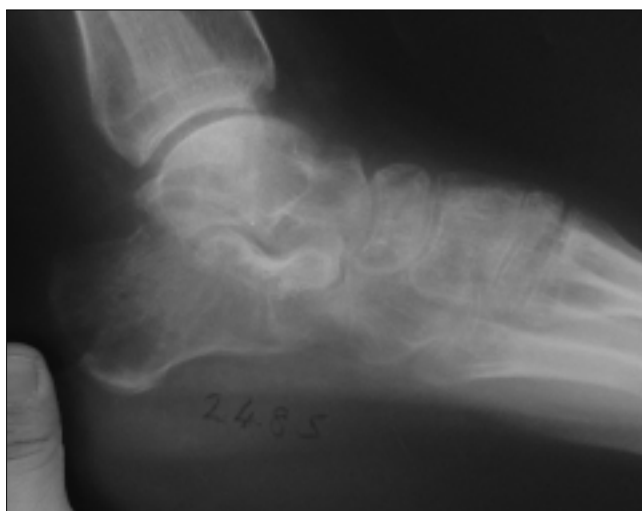

Figure 1. Diffuse osteopenia in right foot

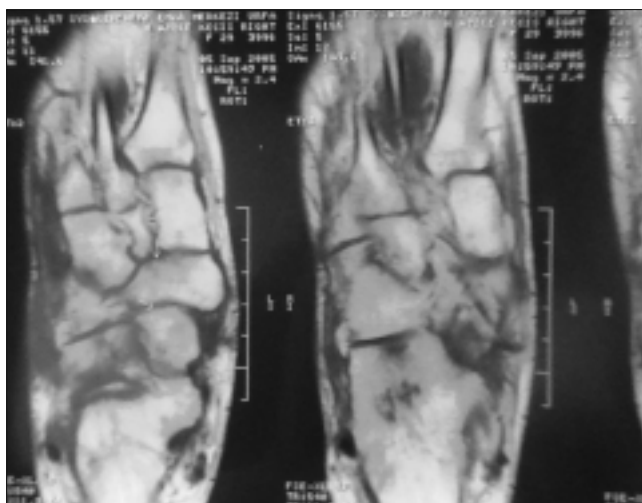


Figure 2. Low signal intensity on T1-weighted images and high signal intensity on T2-weighted images in ankle and foot

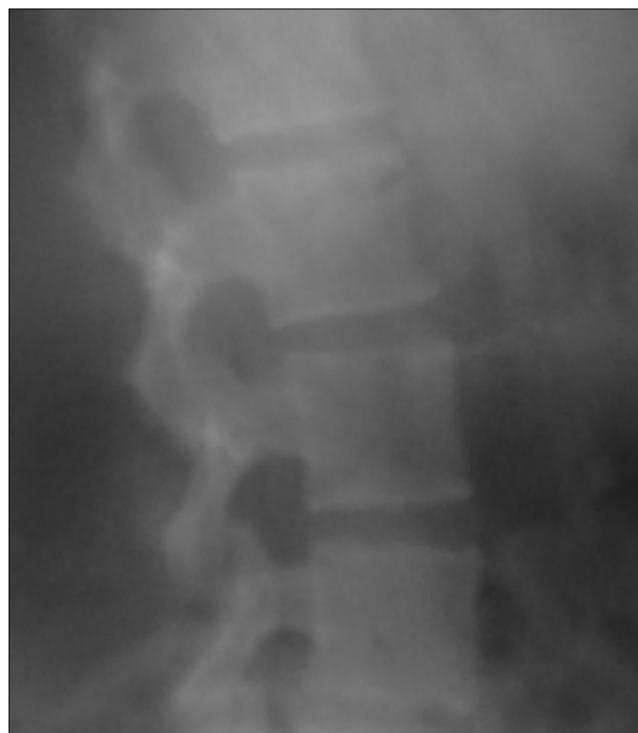

Figure 3. Lateral view of lumbar spine

## Discussion

Pregnancy can alter the course of some inflammatory disorders. It can also lead to the emergence of mechanical joint diseases, such as reflex sympathetic dystrophy of the lower extremities (7). Reflex sympathetic dystrophy is a disease with a wide range of clinical manifestations. Thus, before it was recognized as a single disease, it received a large number of names, such as algodystrophy, Sudeck atrophy, shoulder-hand syndrome, and causalgia. Transient osteoporosis has also been thought by many authors to be a form of reflex sympathetic dystrophy. It has been proposed that an objective differentiation was not possible between them (8). Although pathogenetic mechanism of the disease is not totally clear, sympathetic regulation of micro vessels is certainly (9).

Transient osteoporosis in pregnancy was first described by Curtiss and Kincaid (10) in three cases of transient demineralization of the hip during pregnancy. Lequesne (4) in 1968 described the same pathology and called it transient osteoporosis or RSD. De Marchi et al. (11) reported five men

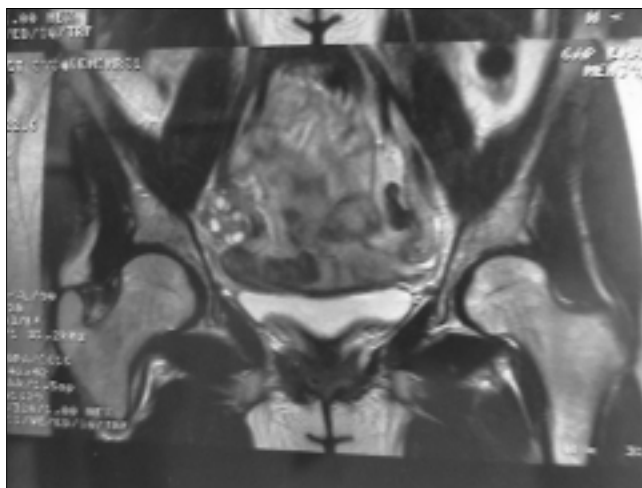


Figure 4. Normal Hip MRI

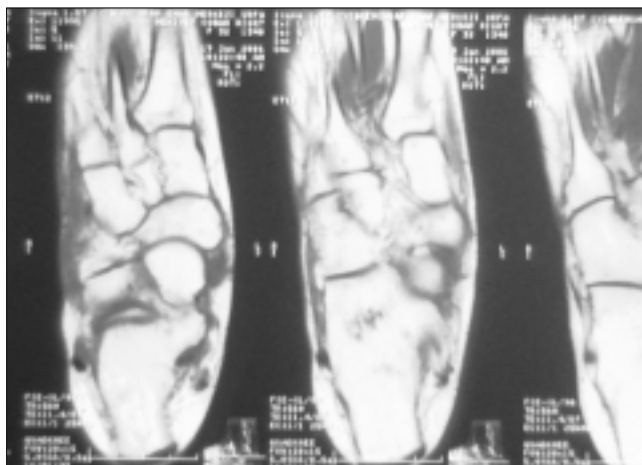


Figure 5. Resolution of bone marrow oedema in foot and ankle bones in MRI

and a woman with the same clinical picture. Later, additional reports of cases have been appeared and further defined, but the different terms was used to determine the same condition in each case. In 1994, a working group of the International Association for the Study of Pain (IASP) developed a consensus definition and proposed a new terminology. Thus, the term complex regional pain syndrome (CRPS) type I replaces the name RSD, and the term CRPS type II, which requires demonstrable peripheral injury, replaces the term causalgia (12).

The pathophysiology of transient osteoporosis which occurs in pregnancy is contributed to microtrauma in weight-bearing bones or chemical alterations. It has been proposed regarding the pathogenetic mechanism which an unknown stimulus activates a large number of bone turnover foci in the involved joint, initiating intensive osteoclast resorption. (13,14). There are relatively rare reports on this issue, but the association of RSD and pregnancy does not randomly appear. Factors which contribute to RSD related to pregnancy have not been elucidated. During pregnancy, significant weight gain, hyperlordosis, hypertriglyceridemia, vascular stasis induced by the compression on the inferior vena cava may be risk factors for RSD (7).

The relation between RSD and transient osteoporosis remains controversial, but pathophysiology and clinical findings appears to be same. However, RSD often associated with sensory, motor, and autonomic disturbances as well as trophic changes, such as increased hair growth, redness, and warmth (15). But, patients with transient osteoporosis presented with only pain and osteoporosis. We preferred to name it as RSD of foot in pregnancy because the clinical findings of our patient met the diagnostic criteria for CRPS type I.

We described the pregnant patient with RSD of the foot and ankle. We thought that RSD should be included in the differential diagnosis of patients with acute foot and ankle pain. Failure to recognize this unusual cause of pain can result in delayed or mistaken diagnosis especially during pregnancy. The recognition of this condition provides us to avoid invasive investigations in pregnant women.

## References

1. Siminoski K, Fitzgerald AA, Flesch G, Gross MS. Intravenous pamidronate for treatment of reflex sympathetic dystrophy during breast feeding. *J Bone Miner Res* 2000; 15: 2052-5.
2. Sergent F, Mouroko D, Sellam R, Marpeau L. Reflex sympathetic dystrophy involving the ankle in pregnancy: characteristics and therapeutic management. *Gynecol Obstet Fertil* 2003; 31: 543-5.
3. Alvarez-Lario B, Aretxabala-Alcibar I, Alegre-Lopez J, Alanso-Valdivielso JL. Acceptance of the different denominations for reflex sympathetic dystrophy. *Ann Rheum Dis* 2001; 60: 77-9.
4. Lequesne M. Decalcifying algodystrophy of the hip. A series of 10 cases. *Rev Rhum Mal Osteoartic* 1968; 35: 183-95.
5. Herrick A, El-Hadidy K, Marsh D, Jayson M. Abnormal thermoregulatory responses in patients with reflex sympathetic dystrophy syndrome. *J Rheumatol* 1994; 21: 1319-24.

6. Curtiss PH Jr, Kincaid WR. Transitory demineralization of the hip in pregnancy. A report of three cases. *J Bone Joint Surg Am* 1959; 41: 1327-33.
7. Poncelet C, Perdu M, Levy-Weil F, Philippe HJ, Nisand I. Reflex sympathetic dystrophy in pregnancy: nine cases and a review of the literature. *Eur J Obstet Gynecol Reprod Biol* 1999; 86: 55-63.
8. Castellano K, Plantalech L. Regional transient osteoporosis, and reflex sympathetic dystrophy: the same disease? *Medicina (B Aires)* 2005; 65: 425-8.
9. Bennett DS, Brookoff D. Complex regional pain syndromes (reflex sympathetic dystrophy and causalgia) and spinal cord stimulation. *Pain Med* 2006; 7: 64-96.
10. Curtiss PH Jr, Kincaid WR. Transitory demineralization of the hip in pregnancy. A report of three cases. *J Bone Joint Surg Am* 1959; 41: 1327-33.
11. De Marchi E, Santacroce A, Solarino GB. On an unusual rarefying hip arthropathy. *Arch Putti Chir Organi Mov* 1966; 21: 62-75.
12. Reinders MF, Geertzen JH, Dijkstra PU. Complex regional pain syndrome type I: use of the International Association for the Study of Pain diagnostic criteria defined in 1994. *Clin J Pain* 2002; 18: 207-15.
13. Cayla J, Chauat D, Rondier J, Guerin K, Frugier JC. Reflex algodystrophy of the lower limbs during pregnancy. *Rev Rhum Mal Osteoartic* 1978; 45: 89-94.
14. Harden RN, Swan M, King A, Costa B, Barthel J. Treatment of complex regional pain syndrome: functional restoration. *Clin J Pain* 2006; 22: 420-4.
15. Schweitzer ME, Mandel S, Schwartzman RJ, Knobler RL, Tahmoush AJ. Reflex sympathetic dystrophy revisited: MR imaging findings before and after infusion of contrast material. *Radiology*. 1995; 195: 211-4.