

A Case of Axial Spondyloarthritis without Sacroiliitis

Sakroileit İzlenmeyen Belirgin Radyografik Spondilitli Bir Aksiyel Spondilartrit Olgusu

Ümit Seçkin, Hatice Bodur, Filiz Eser

Ankara Numune Eğitim ve Araştırma Hastanesi, Fizik Tedavi ve Rehabilitasyon Kilingi, Ankara, Türkiye

Abstract

Our case is an HLA B27-positive 60-year-old female patient who had been suffering from inflammatory back and heel pain for 10 years. While sacroiliitis was not observed on either magnetic resonance imaging or pelvic X-ray, all possible radiographic findings of axial spondylitis and enthesopathy were observed on the radiographs, including bamboo spine and trolley track sign. We thus stress the diagnostic difficulties.

(*Turk J Rheumatol 2009; 24: 166-9*)

Key words: Spondyloarthritis, sacroiliitis, radiographic signs

Received: 27.03.2008

Accepted: 10.07.2008

Özet

Olgumuz 10 yıldır inflamatuvar bel ve topuk ağrısı olan, HLA B27 pozitif, 60 yaşında bir bayan hasta. Sakroiliak eklemlerin radyografik ve manyetik rezonans görüntülemesinde sakroileit saptanmadı. Buna karşın bambu kamışı, üçlü ray görüntüsü dahil olmak üzere radyografik spondilit ve entesopati bulgularının tümü mevcuttu. Bu olgu nedeniyle tanısız güçlük vurgulanmaktadır.

(*Turk J Rheumatol 2009; 24: 166-9*)

Anahtar Sözcükler: Spondiloartrit, sakroileit, radyografik bulgular

Alındığı Tarih: 27.03.2008

Kabul Tarihi: 10.07.2008

Introduction

Patients who do not show sacroiliitis although they suffer from long time inflammatory back pain (IBP) and have marked radiographic axial spondylitis findings are not very common in literature. Here we present a HLA B27 positive case of axial spondyloarthritis with obvious radiographic spondylitis and enthesopathies without sacroiliitis.

CASE

A 60-years old patient came to our clinic with complaints of back pain for 10 years. We learned that her pain increases with resting and decreases with movement. She had a history of bilateral heel and alternate buttock pain also. She experienced temporary benefit from nonsteroidal anti-inflammatory drugs. She had morning stiffness for about 2 hours.

Her systemic examination findings were normal. On spine examination, her cervical and lumbar spinal movements were painful and limited. Her tragus-wall

distance was 19 cm, occiput-wall distance was 6 cm and chin-manubriosternal distance was 3 cm while lumbar-laterally flexion were 6, 5 cm and the modified Schober test was 1,5 cm. There was an increase in her thoracic kyphosis. Her chest expansion was 2,5 cm. Bilateral shoulder movements were painful and right shoulder movements were limited while her bilateral hip rotations were painful and limited.

Her hemogram and routine biochemical analysis were in normal range, erythrocyte sedimentation rate 54 mm/hour (normal:0- 12), C-reactive protein 118 mg/L (normal:0-5), rheumatoid factor (RF) was negative. Brucella agglutination tests were negative. Urine test was normal. No infection was established in her examination and tests. Her HLA B27 was positive and Bath Ankylosing Spondylitis Disease Activity Index (BASDAI) was calculated as 6.7.

Her postero-anterior chest x-ray was evaluated as normal. In thoracic (Picture 1) and lumbosacral (Picture 2) graphs, marked squaring in her vertebrae, shiny corners, symmetric syndesmophytes, bamboo spine, trolley track

21. Ulusal Fiziksel Tıp ve Rehabilitasyon Kongresi'nde poster olarak sunulmuş ve özet kitabında yayınlanmıştır

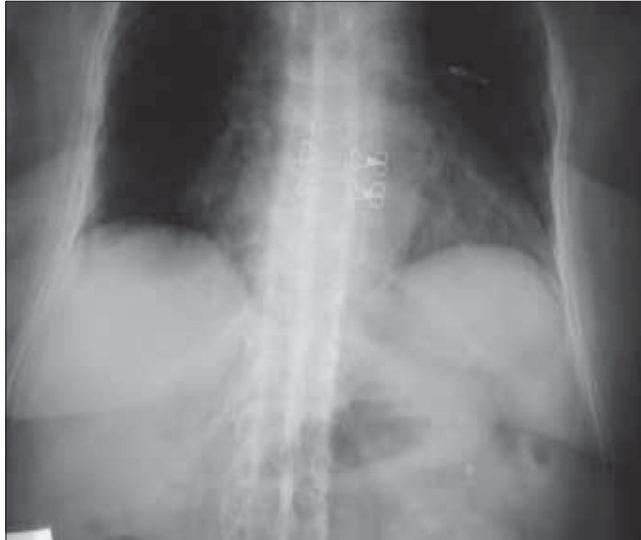
Address for Correspondence / Yazışma Adresi: Dr. Filiz Eser, Ankara Numune Eğitim ve Araştırma Hastanesi, Fizik Tedavi ve Rehabilitasyon Kilingi, Ankara, Türkiye Phone: +90 312 508 48 03 E-mail: filizeser@gmail.com

sign, osteoporosis and left faced scoliosis were observed. In pelvic x-ray her sacroiliac joints were normal. There were enthesopathic changes in the localization of the insertion of achilles tendon in calcaneus posterior bilaterally (picture 3). In magnetic resonance imaging (MRI) and conventional radiography, bilateral sacroiliac joints were regular and joints cartilage were normal (Picture 4,5). There were not any pathological signal changes in the bone surfaces that

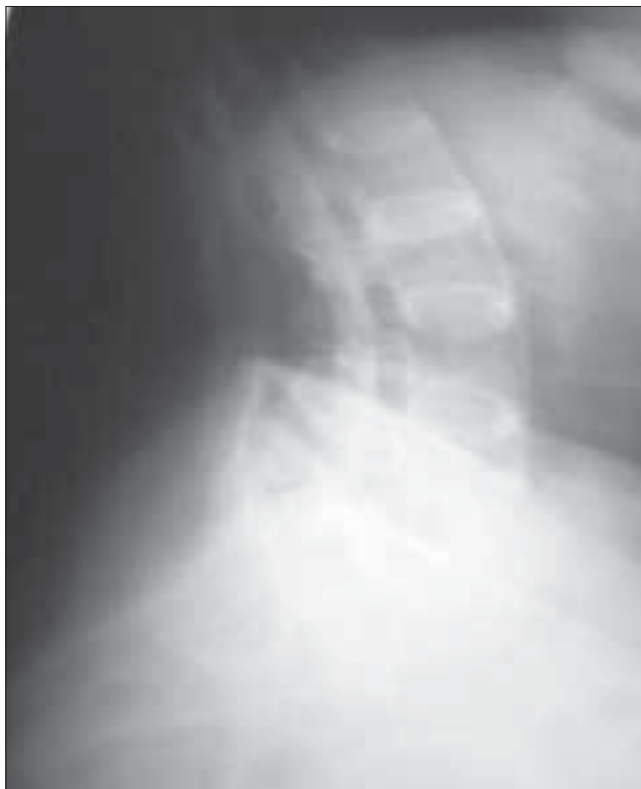form the joints and the soft structures that were examined. Depending on the current clinical status and the radiography and imaging tests, the patient was defined as spondyloarthropathy (SpA).

Discussion

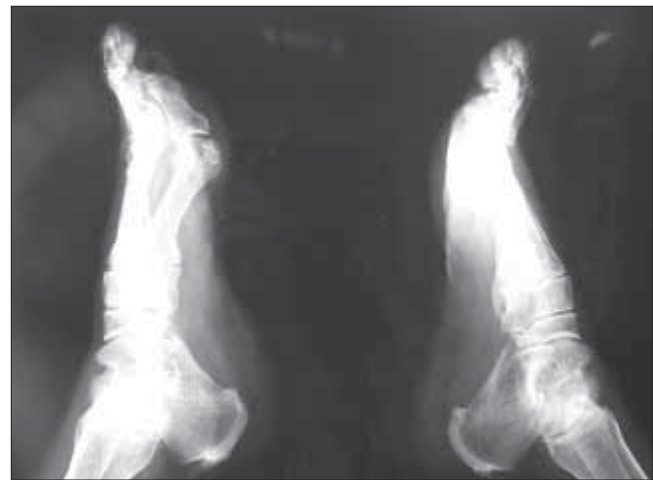Diagnosing axial SpA [Ankylosing Spondylitis (AS) and undifferentiated SpA(uSpA) with predominant axial involvement but without radiographic sacroiliitis] in the absence of radiographic sacroiliitis poses a major challenge to many physicians. In the absence of diagnostic criteria, classification criteria are often used to aid the diagnostic process in daily practice. The most often cited classification criteria for SpA are the European Spondylarthropathies Study Group (ESSG) criteria that were proposed in 1991. According to these criteria, in the absence of sacroiliitis;



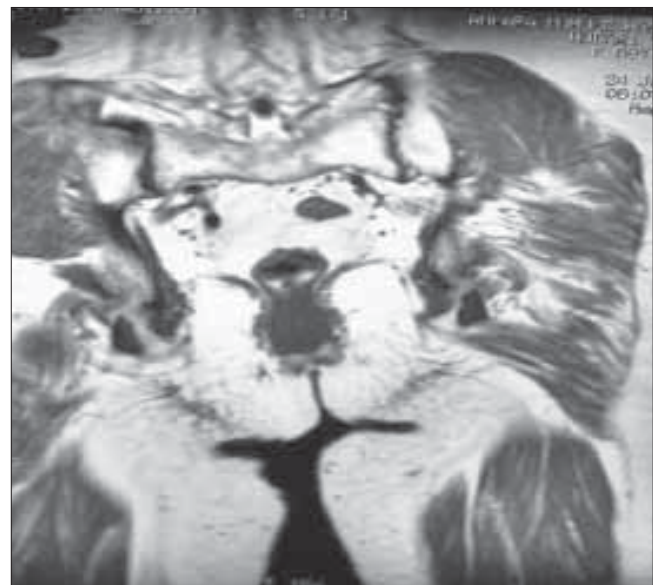
Picture 1. Thoracic X-ray



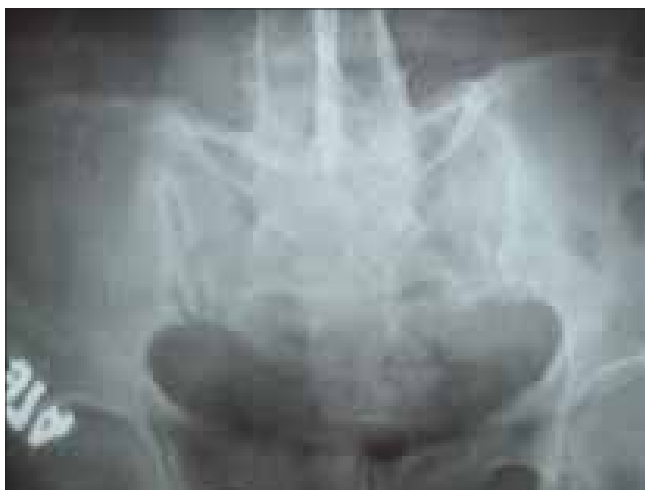Picture 2. Lumbosacral X-ray



Picture 3. Calcaneal X-ray



Picture 4. Sacroiliac magnetic resonance imaging



Picture 5. Conventional sacroiliac X-ray

patients with inflammatory spinal pain or synovitis (asymmetric, predominantly in the lower limbs) in addition to any one of the following (positive family history, psoriasis, inflammatory bowel disease, alternate buttock pain, enthesopathy) are classified as seronegative SpA with 77% sensitivity and 89% specificity. In the presence of sacroiliitis, sensitivity is 86% and specificity is 87% (1). However in a recent study from Spain, it was observed that the performance of the ESSG criteria as diagnostic criteria in daily practice was moderate: only 46.6% of patients with possible SpA who met the ESSG criteria at entry into the study were judged by their rheumatologist to have SpA after 5 years of follow up (2). The typical radiographic changes of AS are seen primarily in the axial skeleton, especially in the sacroiliac, discovertebral, apophyseal, costovertebral, and costotransvers joints (3). Syndesmophytes seen in AS and entheropathic arthrititis are usually symmetrical and bilateral, while that are seen in reactive arthrititis and psoriatic arthrititis are nonmarginal, rough and asymmetrically located (4). The radiological appearance of arthritic changes in sacroiliac joints has been regarded as a hallmark of AS according to Modified New York Criteria (5). In AS patients in addition to sacroiliitis, arthritic changes in the spine visualized by x-ray develop in 57- 88% of the patients (6, 7). In literature, there were AS patients with typical clinical features but no radiological sacroiliitis (8). Khan et al reported that radiographic sacroiliitis is frequent in AS but is not an early or obligate manifestation of the disease. In particular, relatives of AS with IBP may not show radiographic sacroiliitis even after long follow-up (9). Rudwaleit reported that in a small proportion of AS patients may never develop radiographic sacroiliitis despite having IBP for many years. SpA patients with predominantly axial symptoms should be considered as having a same disease entity as AS patients, independent from the presence of radiographic sacroiliitis (10). In one study 60% of SpA

patients had developed definite AS after 10 years of follow-up. It took an average of 9 years (+/-6 years) for radiological sacroiliitis to appear in these patients. A further 20% still had chronic uSpA and might have developed radiological sacroiliitis if their follow-up had been continued for a longer time (11). Again in another family study, radiographic evidence of sacroiliitis was found in 40% of patients with a symptom duration of <10 years, 70% with symptoms for 10-19 years, and 86% with symptoms for \geq 20 years (12). The morphological changes used to assess spinal involvement in x-ray were syndesmophytes, shining corners, squaring, arthrititis of the apophyseal joints, spondylodiscitis, bamboo spine and trolley track sign (13). Descriptions of spinal x-ray changes typical of AS without concomitant radiological sacroiliitis are thus relatively uncommon. Besides, Moll reported that these spinal x-ray changes develop later in the course of AS and usually after radiological sacroiliitis is evident. (14). MRI is considered to be very helpful in detecting signs of sacroiliitis that are not yet visible in x-ray (15). Although our HLA B27 positive patient has been suffering from IBP for 10 years, no sacroiliitis was detected in her pelvic x-ray and MRI. However in her thoracic and lumbar x-ray, all radiological abnormalities such as squaring, shiny corner, syndesmophytes, bamboo spine, trolley track sign were clearly present. In her foot x-ray, bilateral calcaneal enthesopathy was detected.

It has recently been showed that patients with early disease without radiographic sacroiliitis (uSpA with axial involvement) do not differ in this regard from patients with definite AS (with radiographic sacroiliitis) of short duration (<10 years) with respect to disease activity (as evaluated by BASDAI) (16). In our case; BASDAI score was 6.7 and the disease was considered active also.

Depending on all these findings; we want to focus on the possibility of patients with long term spondyloarthropathies features who have typical radiographic changes of axial spondylitis without sacroiliitis. That is why we strongly believe the importance of the classification criteria in order to avoid misclassification.

Conflict of Interest

No conflict of interest is declared by authors.

References

1. Dougados M, Van der Linden S, Juhlin R. The European Spondyloarthropathy Study Group preliminary criteria for the classification of spondyloarthropathy. *Arthritis Rheum* 1991; 34: 1218-27.
2. Collantes E, Veroz R, Escudero A, Munoz E, Munoz MC, Ciscal A, et al. Can some cases of 'possible' spondyloarthropathy be classified as definite or undifferentiated spondyloarthropathy? Value of criteria for spondyloarthropathies. *Spanish Spondyloarthropathy Study Group. Joint Bone Spine* 2000; 67: 516-20.
3. Van der Linden SM, Van der Heijde D, Braun J. *Ankylosing Spondylitis*. In: Kelley's Textbook of Rheumatology. Philadelphia: Pennsylvania, 2005; 1125-41.

4. Van der Linden SM, Valkenburg HA, Cats A. Evaluation of diagnostic criteria for ankylosing spondylitis: a proposal for modification of the New York criteria. *Arthritis Rheum* 1984; 27: 361.
5. Gümüşdiş G, Doğanavşargil E. Klinik Romatoloji. Spondiloartritler. Klinik Romatoloji. İstanbul: Deniz Matbaası, 1999; 441-65.
6. Carette S, Graham D, Little H, Rubenstein J, Rosen P. The natural disease course of ankylosing spondylitis. *Arthritis Rheum* 1983; 26: 186-90.
7. Prasad P, Sing RP. Ankylosing Spondylitis in Tribalt belt of Chhotanagpur region. *J Indian Med Assoc* 1982; 78: 108-12.
8. Van der Linden SM, Valkenburg HA, de Jongh BM, Cats A. The risk of developing ankylosing spondylitis in HLA-B27 individuals: a comparison of relatives of spondylitis patients with the general population. *Arthritis Rheum* 1984; 27: 241.
9. Khan MA, van der Linden SM, Kushner I, Valkenburg HA, Cats A. Spondylitic disease without radiologic evidence of sacroiliitis in relatives of HLA B27 positive ankylosing spondylitis patients. *Arthritis Rheum* 1985; 28: 40-3.
10. Rudwaleit M, Khan MA, Siepel J. The challenge of diagnosis and classification in early ankylosing spondylitis. Do we need new criteria? *Arthritis Rheum* 2005; 52: 1000-8.
11. Mau W, Zeidler H, Mau R, Majevsli A, Freyschmidt J, Stangel W, et al. Clinical features and prognosis of patients with possible ankylosing spondylitis. Result of a one year follow up. *J Rheumatol* 1998; 15: 1109-14.
12. Said Nahal R, Micelli-Richard C, Berthelot JM, Duche A, Dernis-Labous E, Le Blevec G, et al. On behalf of the Groupe Francais D'Etude Genetique Des Spondyarthropathies. The familial form of spondyarthropathy: a clinical study of 115 multiplex families. *Arthritis Rheum* 2000; 43: 1356-65.
13. JT Gran, Husby G, Hordvik M. Spinal ankylosing spondylitis: a variant form of ankylosing spondylitis or a distinct disease entity? *Annals of the Rheum Diseases* 1985; 44, 368-71.
14. Moll JMH. Ankylosing Spondylitis. In: Scott JT, ed. *Copeman's textbook of the rheumatic disease*. 5th ed. Edinburg: Churchill Livingstone, 1978; 511-36.
15. Rudwaleit M, van der Heijde D, Khan MA, Braun J, Sieper J. How to diagnose axial spondyloarthritis early. *Ann Rheum Dis* 2004; 63: 535-43.
16. Rudwaleit M, Listing J, Marker-Hermann E, Zeidler H, Braun J, Springer J. The burden of disease in patients with ankylosing spondylitis (AS) and pre-radiographic axial spondyloarthritis. *Arthritis Rheum* 2004; 50: 211.