

CASE REPORT

Panniculitis, A Rare Presentation of Onset and Exacerbation of Juvenile Dermatomyositis: A Case Report and Literature Review

Yun Jung CHOI , Wan-Hee YOO 

Department of Internal Medicine, Research Institute of Clinical Medicine of Chonbuk National University-Biomedical Research Institute of Chonbuk National University Hospital, Jeon-ju, South Korea

ABSTRACT

Panniculitis occurring in juvenile dermatomyositis has been rarely reported. However, it may lead to poor quality of life, and furthermore, induce an irreversible structural change in the subcutaneous layer. In this article, we present the case of a 10-year-old female patient with panniculitis that simultaneously developed with the onset and flare-up of juvenile dermatomyositis. In addition, a brief literature review of cases regarding juvenile dermatomyositis-associated panniculitis emphasizes the importance of recognizing panniculitis as a cutaneous manifestation of juvenile dermatomyositis.

Keywords: Juvenile dermatomyositis; panniculitis; pediatric; subcutaneous tissue.

Juvenile dermatomyositis (JDM) is an autoimmune disorder characterized by systemic vasculopathy, predominantly involving the muscles and skin with onset during childhood.¹ Pathognomonic cutaneous manifestation may be helpful for the diagnosis of JDM, such as Gottron papules, heliotrope rash, V-sign, and shawl sign¹. As diagnostic criteria involve the characteristic skin manifestation of patients, an awareness of distinctive skin rash enables to make prompt diagnosis and timely management. Besides well-known skin manifestations as described above, panniculitis in patients with JDM has been also reported. Panniculitis is a disease group of subcutaneous adipose tissue inflammation. The concurrent occurrence of JDM and panniculitis is infrequently described; however, several supporting evidences including their vasculitic features and pathologic findings of panniculitis

in JDM suggest their pathogenetic relationship. In this study, we describe a case of JDM with simultaneous panniculitis appearing both during JDM diagnosis and disease flare-up in light of the literature. Our aim was to raise the attention of clinicians on panniculitis as a cutaneous manifestation of JDM, and thereby lead them to keep in mind this rare disease for accurate treatment.

CASE REPORT

A 10-year-old female patient presented with a two-week history of violaceous eruptions with swelling on the palm and heel (Figure 1a and b). The lesion was exceedingly painful; hence, she could not walk without assistance and had functional limitation on daily practice, such as grasping

Received: May 10, 2017 **Accepted:** August 31, 2017 **Published online:** November 02, 2017

Correspondence: Wan-Hee Yoo, MD. Department of Internal Medicine, Research Institute of Clinical Medicine of Chonbuk National University-Biomedical Research Institute of Chonbuk National University Hospital, 20, Geonji-ro, Deokjin-gu, Jeon-ju, South Korea. Tel: 82-63-250-2579 e-mail: ywhim@jbnu.ac.kr

Citation:

Choi YJ, Yoo WH. Panniculitis, A Rare Presentation of Onset and Exacerbation of Juvenile Dermatomyositis: A Case Report and Literature Review. Arch Rheumatol 2018;33(3):367-371.

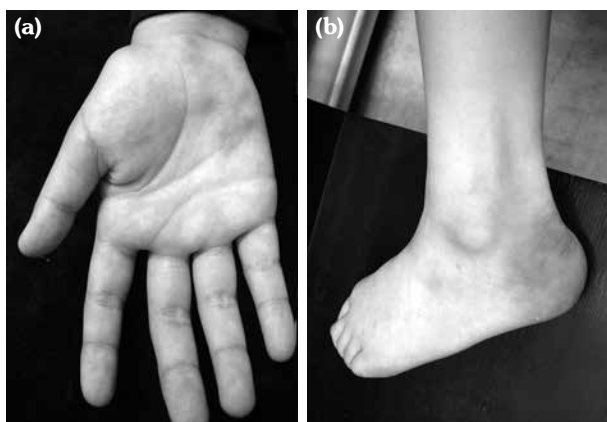

Figure 1. Indurated, erythematous plaques on (a) palm and (b) heel.

a pencil. She had no significant personal or family history. The patient also had mild reddish and scaly rashes on her elbows, which were not painful, and she could not recall when they appeared. She underwent a cutaneous biopsy on the heel, and laboratory assessments and imaging tests were performed. The patient was initially treated with antibiotics because we could not exclude an infectious origin, such as cellulitis. A written informed consent was obtained from the patient.

In a subsequent visit after one week, no symptomatic improvement was noted, and she complained of lower extremity weakness. The skin biopsy results revealed lobular panniculitis consisting of mixed neutrophilic and lymphocytic infiltration. Calcification or vasculitis was absent (Figure 2). The magnetic

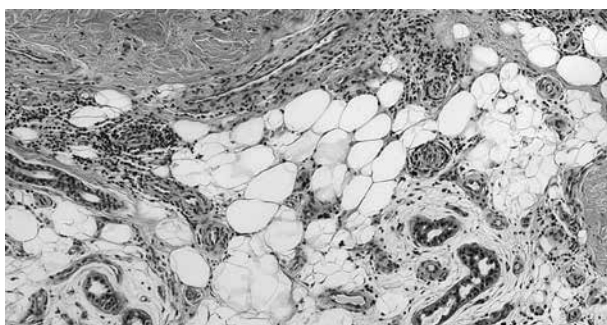


Figure 2. A skin biopsy of left foot lateral side revealed lobular panniculitis with neutrophilic and lymphocytic inflammatory infiltrates in subcutaneous fat layer. No calcification or feature of vasculitis was observed (H-E \times 100).

resonance images (MRI) revealed diffuse hyper-intense signal of the multiple muscles in the upper arm and thigh (Figure 3a and b). Laboratory tests yielded insignificant findings, except for aldolase (17.8 IU/mL; physiological range $<$ 7.6 IU/mL) and lactate dehydrogenase (799 IU/L; physiological range, 218-472 IU/L). Autoantibodies for antinuclear antibodies, including anti-Jo 1 antibody were not detected. A muscle biopsy specimen was obtained from a muscle in the thigh because JDM was suspected, and results were compatible with JDM. Based on the clinical and pathologic findings, JDM and JDM-associated panniculitis were diagnosed.

Treatment was initiated with intravenous methylprednisolone (2 mg/kg) and azathioprine (75 mg/day). Clinical improvement was noted within three weeks, with normalization of muscle power and resolution of pain and swelling of the heel and palm. She remained in tolerable state until steroid dose was tapered to 5 mg twice daily with azathioprine by six months.

However, she was readmitted owing to the same manifestations occurring after the medication was stopped for a few days. Erythematous nodules appeared on her palm and sole, and she also complained of lower extremity weakness, similar to that when she was diagnosed. Increased muscular signal changes were found in the upper and lower extremity

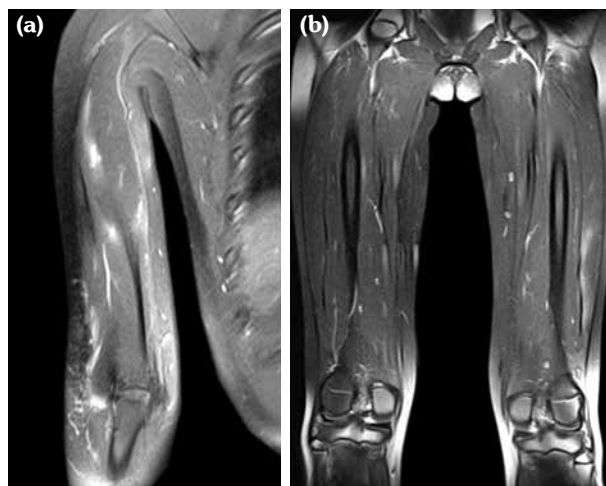


Figure 3. Magnetic resonance imaging of both thigh muscles and proximal arm muscles. Coronal T₂-weighted images show high signal changes and enhancement on (a) proximal arm muscles and (b) thigh muscles.

Table 1. Characteristics of previously documented cases of panniculitis in juvenile dermatomyositis

Case No.	Sex/Age	Nationality	Onset of panniculitis relative to manifestation of DM	Localization of the lesion	Histologic findings	Treatment	Response to treatment and interval to final response	References
1	M/2	Japan	7 months later	Arms, chest and buttocks	Non-suppurative panniculitis, ischemic adipo-necrosis, accompanied by perivascular plasmocyte and lymphocyte infiltration	Prednisone 25 mg/day	6 weeks, resolved	8
2	M/7	Australia	1 year later	Buttocks, thighs and arms	Lobular panniculitis. A slight patchy myxoid change within the fat lobules without calcification or vasculitis	Prednisone 2 mg/kg/day	Improved/ N/A	6
3	F/3	USA	3 months later	Arm	Lobular necrotizing panniculitis without calcification	Prednisone 1 mg/kg/day	Resolved/ N/A	9
4	M/14	USA	4 years later	Forearm, thigh, flank	Lobular panniculitis with lymphocytes and plasma cells without calcification	Hydroxychloroquine 400 mg/day, Prednisone 0.3 mg/kg/day	Resolved/ 2 weeks	10
5	F/15	Spain	5 years later	Proximal upper and lower extremities and Back	Dense lymphohistiocytic infiltrate with several plasma cells in the lobules of the subcutaneous fat, preserving the septum without calcification or vasculitis	Intravenous methylprednisolone bolus for 3 times (0.5 mg/kg), Oral prednisone 60 mg/day, cyclosporin 300	Resolved/ 4 weeks	11
6	F/15 years	Turkey	Simultaneously	Thighs	Lobular panniculitis with calcification	Prednisone 1 mg/kg/day	Improved/ 2 weeks	12
Present case	F/10	South Korea	Simultaneously	Palm and heel		Prednisone 2 mg/kg/day, Azathioprine 75 mg/day	Improved/ 3 weeks	

DM: Dermatomyositis; N/A: Not available.

MRI, and elevated muscle enzymes indicated JDM flare-up. The patient was administered with intravenous methylprednisolone (2 mg/kg) for three boluses and oral prednisolone (40 mg daily) with azathioprine. Skin lesions and muscle weakness resolved within one week. She was discharged with a well-tolerated state with 20 mg prednisolone daily and azathioprine at the same dosage.

DISCUSSION

Juvenile dermatomyositis is a rare autoimmune disorder with the incidence of approximately two to three cases per million children,² so it is challenging for clinicians to diagnose the disease without characteristic and distinguishing manifestations. In addition to subject symptoms such as muscle weakness, pathognomonic

cutaneous symptom could be a critical clue for a suspicion of JDM. Panniculitis is also reported to be a cutaneous manifestation of JDM, although it is relatively uncommon. Reviewing the literature, we detected seven such cases and reported the first documented case of JDM-related panniculitis to our knowledge occurring both during disease onset and flare-up simultaneously.

Panniculitis is a group of heterogeneous inflammatory diseases that involves the subcutaneous adipose tissue.³ It commonly presents with erythematous, indurated subcutaneous nodules accompanied by tenderness and heating sensation and can result in calcifications and lipo-atrophy.⁴⁻⁶ Although it is infrequently reported, according to an analysis based on histologic examination with 55 patients with DM, panniculitis was detected at a prevalence of 10%.⁷ This discrepancy between pathologic studies and clinical reports may lead to a speculation that panniculitis is unrecognized clinically or under-reported. Panniculitis in patients with JDM has been documented in seven cases (Table 1),^{6,8-12} and we excluded the cases complicated with infections. The predilection sites were the extremities and buttocks, but eruptions were also observed in the palm and heels, as in our case. The mean age of patients was 11.5 years, and three of the seven patients were male. The histopathologic findings were similar. Lobular panniculitis without calcification or vasculitis was mostly found, except one case containing calcification. The onset time of panniculitis was diverse from concurrently to five years after JDM diagnosis, which is approximately three years after the diagnosis on average. The mainstay of treatment was high-dose steroid, and responses to steroid were mostly remarkable within a few weeks.

The changes of the subcutaneous layer, such as lymphocytic panniculitis, are described frequently in JDM, yet these changes are focal or subclinical and not specific enough to diagnose JDM-associated panniculitis.¹³ Therefore, diagnosis of JDM-related panniculitis should be established by confirmation of histopathologic examination in a setting of JDM after exclusion of other causes leading to panniculitis.¹⁴ However, patterns of JDM-associated panniculitis commonly revealed mostly lobular panniculitis

with lymphoplasmacytic infiltration. It is similar to lupus profundus, one of the most frequent panniculitis occurring in connective tissue disease in childhood; on the other hand, the presence of mucin deposit differentiates lupus profundus from JDM-associated panniculitis.¹⁵

Although the relationship between panniculitis and JDM has not been elucidated, the clinical situations of concomitant occurrence of muscle weakness and panniculitis raise the possibility that these illnesses are associated pathogenetically. This is also supported by the histologic findings of segmental acute inflammation of arterioles or thickening of the vessel wall in the adipose tissue of patients with JDM.^{13,16} There may be a time lag in manifestation of panniculitis as of the development of JDM. In general, since patients are vulnerable to infection because of immunosuppressive agent intake, infectious etiology should be excluded in the setting of panniculitis in a patient with JDM.

Owing to a limited number of case reports, treatment of JDM-associated panniculitis is not well-established yet. Considering the cases described, spontaneous regression was not reported, and immunosuppression is thought to be required. Mostly, therapeutic responses to systemic steroid have been excellent, typically 1 mg/kg/day or initially pulse therapy followed by tapered dose of steroid. In our case, both skin manifestation and muscle weakness showed improvement simultaneously after steroid administration. Immunosuppressive agents, including methotrexate, cyclosporine, azathioprine, and intravenous immunoglobulin, might be accompanied with steroid to wean the dosage of steroid and prevent relapses.¹⁷

In conclusion, although panniculitis in JDM is not apparent clinically and is rarely reported, the subclinical changes in the subcutaneous tissue of JDM frequently exist. It may present concurrently with the onset of JDM or a few months later. Therefore, if a patient with JDM manifests with erythematous, painful, indurated eruptions, JDM-associated panniculitis should be considered a possibility. The correlation between histologic findings and clinical course is required to be established in JDM-associated panniculitis, since timely diagnosis and treatment may reduce the pain and improve the quality of life of patients.

Declaration of conflicting interests

The authors declared no conflicts of interest with respect to the authorship and/or publication of this article.

Funding

The authors received no financial support for the research and/or authorship of this article.

REFERENCES

1. Feldman BM, Rider LG, Reed AM, Pachman LM. Juvenile dermatomyositis and other idiopathic inflammatory myopathies of childhood. *Lancet* 2008;371:2201-12.
2. Gary SF, Ralph CB, Sherine EG, Iain BM, James RO. Kelley's textbook of rheumatology. In: Ronald ML, Susanne MB, editors. *Pediatric Systemic Lupus Erythematosus, Dermatomyositis, Scleroderma, and Vasculitis*. 9th ed. China: Elsevier; 2011. p. 1776-82.
3. Requena L. Normal subcutaneous fat, necrosis of adipocytes and classification of the panniculitides. *Semin Cutan Med Surg* 2007;26:66-70.
4. Chao YY, Yang LJ. Dermatomyositis presenting as panniculitis. *Int J Dermatol* 2000;39:141-4.
5. Douvoyiannis M, Litman N, Dulau A, Ilowite NT. Panniculitis, infection, and dermatomyositis: case and literature review. *Clin Rheumatol* 2009;28 Suppl 1:S57-63.
6. Commens C, O'Neill P, Walker G. Dermatomyositis associated with multifocal lipoatrophy. *J Am Acad Dermatol* 1990;22:966-9.
7. Janis JF, Winkelmann RK. Histopathology of the skin in dermatomyositis. A histopathologic study of 55 cases. *Arch Dermatol* 1968;97:640-50.
8. Kimura S, Fukuyama Y. Tubular cytoplasmic inclusions in a case of childhood dermatomyositis with migratory subcutaneous nodules. *Eur J Pediatr* 1977;125:275-83.
9. Neidenbach PJ, Sahn EE, Helton J. Panniculitis in juvenile dermatomyositis. *J Am Acad Dermatol* 1995;33:305-7.
10. Ghali FE, Reed AM, Groben PA, McCauliffe DP. Panniculitis in juvenile dermatomyositis. *Pediatr Dermatol* 1999;16:270-2.
11. Otero Rivas MM, Vicente Villa A, González Lara L, Suñol Capella M, Antón López J, González Enseñat MA. Panniculitis in juvenile dermatomyositis. *Clin Exp Dermatol* 2015;40:574-5.
12. Salman A, Kasapcopur O, Ergun T, Durmus Ucar AN, Demirkesen C. Panniculitis in juvenile dermatomyositis: Report of a case and review of the published work. *J Dermatol* 2016;43:951-3.
13. Winkelmann RK. Panniculitis in connective tissue disease. *Arch Dermatol* 1983;119:336-44.
14. Hansen CB, Callen JP. Connective tissue panniculitis: lupus panniculitis, dermatomyositis, morphea/scleroderma. *Dermatol Ther* 2010;23:341-9.
15. Polcari IC, Stein SL. Panniculitis in childhood. *Dermatol Ther* 2010;23:356-67.
16. Wainger CK, Lever WF. Dermatomyositis; report of three cases with postmortem observations. *Arch Derm Syphilol* 1949;59:196-208.
17. Dourmishev LA, Dourmishev AL, Schwartz RA. Dermatomyositis: cutaneous manifestations of its variants. *Int J Dermatol* 2002;41:625-30.